

The Effect of Vitamin D Prophylaxis on Radiation Induced Pulmonary Damage

Gozde YAZICI^{1*}, Ferah YILDIZ¹, Alper ISKIT², Esra ERDEMLI³, Selcuk SURUCU⁴, Pinar FIRAT⁵, Mutlu HAYRAN⁶, Gokhan OZYIGIT¹ and Mustafa CENGIZ¹

Vitamin D/Fibrosis/Radiation pneumonia/Electron microscopy.

Vitamin D has a selective radio and chemosensitizing effect on tumor cells. In vitro and in vivo studies have shown that vitamin D inhibits collagen gel construction, induces type II pneumocyte proliferation and surfactant synthesis in the lungs, and decreases vascular permeability caused by radiation. The aim of this experimental study was to determine if vitamin D has a protective effect against radiation-induced pulmonary damage. Adult Wistar rats were divided into 4 groups. Group 1 was comprised of control animals. Group 2, which was administered 0.25 µg/kg/day of vitamin D3 for 8 weeks, was the vitamin D control group. Rats in groups 3 and 4 were given 20 Gy right hemithorax radiotherapy, and in addition group 4 was given vitamin D3 treatment, which began the day before the radiotherapy and continued for 8 weeks. At the 8th and the 12th weeks of the study 4 rats from each group were sacrificed. Right lungs were dissected for light and electron microscopic study. The electron microscopy examinations revealed statistically significant differences between group 3 and 4, and in group 4 there was less interstitial inflammation and collagen deposition, and the alveolar structure and the cells lining the alveolar walls were protected. These results confirm that vitamin D has a protective effect against radiation-induced pulmonary toxicity. These findings should be evaluated with further clinical studies.

INTRODUCTION

It has been shown that damage to different cells and the interaction between those cells and others leads to radiation pneumonitis.^{1–3)} Fibrosis, on the other hand, is a complicated tissue response, which is characterized by the accumulation of extracellular matrix proteins and proliferation of fibroblasts. Myofibroblasts proliferate and synthesize collagen matrix proteins. Negative feed back mechanisms control cell activity and the differentiated myofibroblasts die by apopto-

sis. In the formation of fibrosis the negative feed back mechanisms that control the myofibroblasts are not activated.⁴⁾

The antineoplastic activity of vitamin D was first demonstrated in mouse myeloid leukemia cells.⁵⁾ In vitro and in vivo studies have demonstrated vitamin D's inhibitory effect on the growth of breast, colon, prostate, endometrial, bladder, and pancreatic cancers, and osteosarcoma cell lines.^{6–9)} It has also been demonstrated that vitamin D has a selective radiosensitizing effect on cancer cells, without any such effect on fibroblasts.^{7,10)}

Platelet-derived growth factor (PDGF) is synthesized by thrombocytes and macrophages, and is a chemotactic agent for neutrophils, monocytes, and fibroblasts, as well as a growth factor for fibroblasts. PDGF plays a major role in pulmonary fibrosis. It has been reported that vitamin D inhibits DNA synthesis in fibroblasts, which is activated by PDGF.^{11–14)} On the other hand, vitamin D inhibits the transformation of fibroblasts into myofibroblasts, which is induced by TGFβ-1.¹²⁾ Moreover, vitamin D has been shown to inhibit the proliferation of fibroblasts in skin.¹³⁾ In the treatment of myelofibrosis, a disease characterized by over production of collagen in bone marrow, vitamin D was reported to be effective.¹⁴⁾ Furthermore, in the treatment of aggressive fibromatosis, a disease characterized by monoclonal fibroblast proliferation and collagen deposition, the

*Corresponding author: Phone: +903125953680,
Fax: +903123633396,
E-mail: gozdeardic@hotmail.com

¹Department of Radiation Oncology, Hacettepe University, Faculty of Medicine, Ankara, 06100, Turkey; ²Department of Pharmacology Hacettepe University, Faculty of Medicine, Ankara, 06100, Turkey; ³Department of Histology and Embryology Ankara University, Faculty of Medicine, Ankara, Turkey; ⁴Department of Anatomy Hacettepe University, Faculty of Medicine, Ankara, 06100, Turkey; ⁵Department of Pathology, Hacettepe University, Faculty of Medicine, Ankara, 06100, Turkey; ⁶Department of Preventive Oncology Hacettepe University, Faculty of Medicine, Ankara, 06100, Turkey.

Conflict of Interest Notification: Any actual or potential conflicts of interest do not exist.

doi:10.1269/jrr.11033

administration of vitamin D reduced the size of masses that were resistant to surgery, radiotherapy, and tamoxifen.¹⁵⁾

The lungs are the major dose-limiting structures in thoracic irradiation. In different studies symptomatic radiation pneumonitis was observed in 1%–34% of patients; however, radiological changes were observed in 13%–100% of patients.^{16–20)} As the criteria used to define radiation pneumonitis and the volume of the lung that is irradiated varies, it is not possible to compare studies. The proposed mechanisms of radiation pneumonitis and fibrosis are: Damage caused to type II pneumocytes and the release of surfactant into the alveolar space; increased vascular permeability due to endothelial cell damage; the release of cytokines and growth factors, which activate molecular mechanisms that cause fibrosis.^{1–3,21–24)}

The aim of the present experimental study was to determine if vitamin D has a protective effect against radiation-induced pulmonary damage. Right lung of rats were irradiated with a single dose of 20 Gy via 6 MV photons, and the effect of prophylactic vitamin D treatment on radiation-induced pneumonitis and fibrosis was evaluated by light and electron microscopy studies.

MATERIALS AND METHODS

Animals

The study included 32 adult male Wistar rats (200–250 g), the use of which was approved by the Hacettepe University Animal Care and Use Committee. Rats were obtained from the Hacettepe University Experimental Animal Laboratory. Animals were housed 4 per cage in a controlled animal holding room with a 12/12-h light/dark cycle; temperature and relative humidity were continually monitored to provide standard laboratory conditions. Food and water were provided ad libitum. The animals were randomly assigned to 4 groups: Group 1, sham irradiation; group 2, vitamin D3; group 3, radiotherapy; group 4, radiotherapy + vitamin D3.

Irradiation

Before irradiation rats were anesthetized using pentobarbital (60 mg/kg) administered intraperitoneally. The animals were stabilized in the prone position and the right hemithorax of each rat was defined by simulation. The rats were given a single 20-Gy dose with 6 MV photons (Philips SL 25 linear accelerator) to the whole right hemithorax using the SAD (source-axis distance) technique.^{11,18)} Irradiation was performed in one direction, from anterior to posterior, and the depth was calculated from the midline. To provide contour regularity, 1-cm elasto-gel bolus was used. The left thorax and the rest of the body were shielded with a lead block. All procedures, except irradiation, were also performed on the control groups.

Drug

For the drug groups (groups 2 and 4) 0.25 µg/kg/day of vitamin D3 (Calcijex, Abbott Laboratories, North Chicago, USA) was administered subcutaneously.²⁵⁾ The administration of vitamin D3 began 1 day before radiotherapy and continued for 8 weeks. An equal amount of 0.9% NaCl was subcutaneously administered to groups 1 and 3 every day for the 8 weeks.

Morphologic studies

At the 8th and 12th weeks of the study 4 animals from each group were sacrificed for morphological examination. The animals were killed by intraperitoneal high-dose pentobarbital injection, and both lungs were removed from the chests of the animals.

Light microscopy

The lungs were fixed in 10% formaldehyde solution and embedded in paraffin for light microscopic examination after punch biopsies were taken from each right lung for evaluation with electron microscopy. The slices obtained were stained with hematoxylin and eosin (H&E), Masson-trichrome, and toluidine blue. Masson-trichrome stain was used to examine fibrosis, toluidine blue was used to count mast cells, and hyaline membrane formation, macrophage infiltration, and interstitial inflammation were evaluated with H&E. Perivascular and interstitial mast cell counts were evaluated at 10× magnification. Interstitial inflammation, fibrosis, hyaline membrane formation, and macrophage infiltration were evaluated with a semi-quantitative technique and were scored as 0–3. The examinations and the grading were performed by the same pathologist blinded to the treatment groups.

Electron microscopy

Punch biopsies were fixed in 2.5% glutaraldehyde solution in a phosphate tampon of pH 7.4. After 24 h of fixation they were washed with Sorenson's phosphate buffer (SPB). Post-fixation was applied by washing with 1.0% osmium tetroxide solution for 1 h. The samples were dehydrated by passing them through an ethanol series. Following dehydration they were treated with propylene oxide and then blocked with Araldite CY 212. Slices (1–2 µm thick) were stained with toluidine blue-Azur II. Electron microscopy examinations were conducted and 60–90-nm thick slices were taken from chosen fields with a Leica UltracutR (Vienna, Austria) ultramicrotome. Thin slices were contrasted with uranyl acetate and lead citrate, and then were examined under a Leo 906E (80 kV) (Oberkochen, Germany) transmission electron microscope. To score the electron microscopic findings thin sections from each group were examined and various pulmonary radiation damage indicators like neutrophils, edema, extravascular erythrocytes, fibroblasts, collagen bundles, macrophages, mast cells, eosinophils and

Table 1. The comparison of the light microscopic findings at the 12th week. (Group 1: control, Group 2: vitamin D3, Group 3: only irradiation, Group 4: irradiation + vitamin D3)

	Kruskal-Wallis (p value)		Mann-Whitney U (p value)				
	All Groups	Group 1 vs 2	Group 1 vs 3	Group 1 vs 4	Group 2 vs 3	Group 2 vs 4	Group 3 vs 4
Interstitial Inflammation	0.000	0.184	0.008	0.003	0.001	0.001	0.966
Edema	0.011	1.000	0.011	0.028	0.015	0.038	0.967
Bleeding	0.048	0.346	0.089	0.634	0.016	0.169	0.154
Fibrosis	0.171	1.000	0.098	0.317	0.117	0.346	0.381
Macrophage infiltration	0.000	0.121	0.002	0.000	0.026	0.006	0.751
Perivascular Mast Cell Count	0.021	0.331	0.007	0.018	0.076	0.197	0.591
Interstitial Mast Cell Count	0.001	0.022	0.002	0.003	0.013	0.026	0.970

debris collections were counted at 20 areas with 5000 magnification.

STATISTICAL METHODS

The Statistical Package for Social Sciences (SPSS) v.11.0 was used for statistical analyses. As the histological scores were ordinal in nature, the differences in histological findings between the 4 study groups were analyzed using the Kruskal-Wallis test. When an overall statistically significant difference was observed, pairwise comparisons were performed using the Mann-Whitney U test, with a correction for multiple comparisons. A 5% type-I error level was used for the statistical significance cut-off for overall comparisons. The differences between the electron microscopic scoring for groups with and without vitamin D and weeks 8 and 12 were compared using the Mann-Whitney U test. The overall comparisons for groups were also performed using the Kruskal-Wallis test.

RESULTS

Light microscopy findings

Light microscopy examinations revealed no differences in fibrosis scores between the groups. Statistically significant differences in interstitial inflammation, edema, bleeding, macrophage infiltration, interstitial mast cell count, and perivascular mast cell count were observed between groups 3 and 4, and groups 1 and 2; however, no differences were observed between groups 3 and 4 (Table 1).

Electron microscopic findings

The eight week electron microscopic examinations revealed statistically significant differences in edema, extravascular erythrocytes, fibroblasts, collagen bundles, macrophages, mast cells, eosinophils, and debris collection between groups 3 and 4. The differences between the groups

Table 2. The comparison of the electron microscopic findings of groups that received irradiation alone (group 3) versus irradiation + vitamin D (group 4)

	Kruskal-Wallis (p value)	Mann-Whitney U (p value)	
	Group3 vs 4	Week 8	Week 12
Neutrophile count	0.022	0.076	0.152
Edema	0.005	0.002	0.278
Extravascular erythrocytes	0.006	0.019	0.039
Fibroblast count	0.012	0.045	0.101
Collagen bundles	0.000	0.014	0.000
Macrophage counts	0.216	0.042	0.004
Perivascular Mast Cells	0.000	0.000	0.018
Eosinophil Cell Count	0.022	0.019	0.032
Debris collection	0.000	0.002	0.019

for extravascular erythrocytes, collagen bundles, macrophages, mast cells, eosinophils and debris collection were still statistically significant at the twelfth week evaluations. The overall comparisons showed statistically significant differences for all the pulmonary radiation damage indicators but the macrophage count (Table 2).

The eighth-week evaluation of the rats in group 3 showed that there was an increase in mast cells and eosinophils in the perivascular space, and that the epithelial cells that lined the alveoli were damaged and desquamated. Serous fluid accumulation and bleeding were observed in the alveolar space, and the alveolar space was narrowed. Accumulation of connective tissue and collagen bundles, cell infiltration, and an increase in the number of fibrocytes were the principal findings observed in the interstitial field (Fig. 1A–B).

The eighth-week examination of the rats in group 4 revealed that there were no exudates or bleeding in the alve-

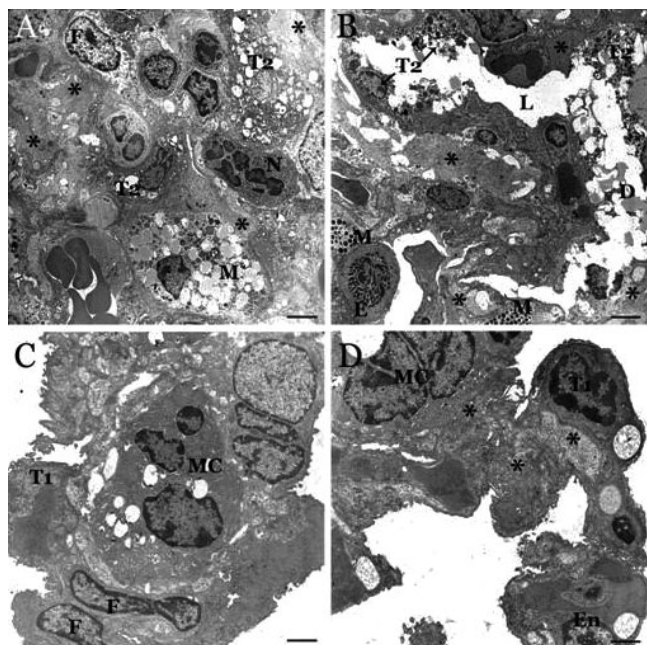


Fig. 1. Eighth-week electron micrographs of the lungs of rats that received radiotherapy alone (A and B), and radiotherapy + vitamin D3 (C and D). **A.** Mast cell (M), eosinophil (E), and neutrophil cell (N) infiltration. Surfactant, including granules of type II pneumocytes (T2), are discharged. Connective tissue accumulation with increasing number of fibrocytes (F) and increased thickness of collagen fiber bundles (*) in interstitial field. **B.** Narrowing of the alveolar lumen (L) with degenerative type II pneumocytes (T2) and exudative debris (D). **C.** Infiltration of macrophage (Mc) in the interstitial field and normal type I pneumocyte (T1). **D.** Mc in the interstitial field, open lumens of the alveoli, and healthy T1; collagen accumulation is decreased. In A and B, bar is 3.0 μm , and in C and D, bar is 6.0 μm .

olar sacs, and the cells that line the alveolar walls had not degenerated and were healthier than those in group 3 rats. In contrast to group 3, there was less cell infiltration in the interstitial field among the group 4 rats. There was a distinct decrease in the number of mast cells and eosinophils in group 4; however, there were more macrophages. Collagen fibers were observed in the interstitial field of group 4 rats, but again, when compared to group 3 the amount was clearly less, and the collagen fibers were not organized (Fig. 1C–D).

Twelfth-week evaluation findings were similar to the eighth-week findings. Dense inflammation, collagen fiber accumulation, and organization of the fibers into large bundles continued in group 3. Fibrosis was observed to increase in the interstitial field, serous fluid accumulation continued in the alveolar lumen, and the cells that line the alveolar wall were degenerated (Fig. 2A–B).

In group 4, twelfth-week findings showed that alveolar lumens were vacant, cells that lined the alveolar walls were healthy, and there was no bleeding in alveolar lumens. In the

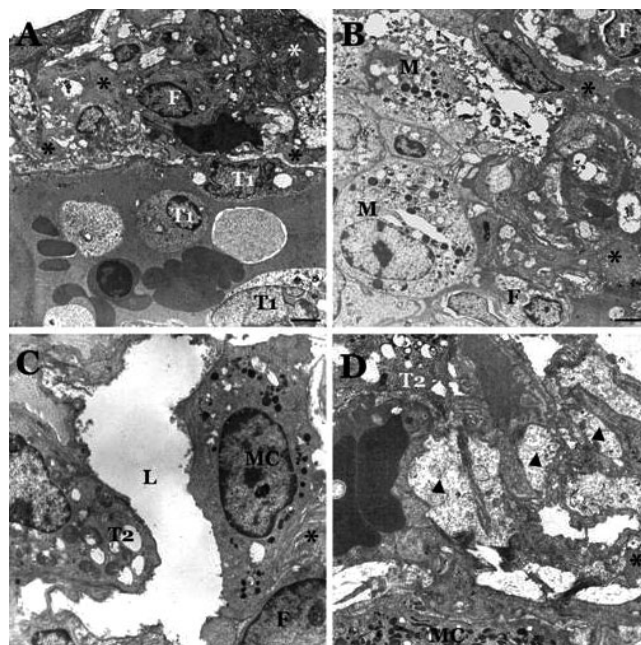


Fig. 2. Twelfth-week electron micrographs of the lungs of rats that received radiotherapy alone (A and B), and radiotherapy and vitamin D3 (C and D). **A.** Alveolar lumen is filled with exudates, sloughing off pneumocytes (T1) and bleeding. Collagen fiber bundles (*) are organized showing fibrosis. **B.** M infiltration and degeneration are observed in the interstitial field. **C.** The lumen of alveoli, which are surrounded with Mc and T2, is clear. **D.** Edema and unorganized collagen fiber bundles in the interstitial field. In A and B, bar is 3.0 μm , in C, bar is 5 μm , and in D, bar is 6.0 μm .

interstitial space neither collagen fibers nor signs of inflammation were observed. In contrast to group 3, fibrosis was not observed in group 4 (Fig. 2C–D).

DISCUSSION

Previously, it was believed that radiotherapy decreases the number of pulmonary parenchymal cells or vessel cells, which results in pulmonary damage, and that this damage is neither preventable nor treatable. However, studies performed in the past few years showed that late tissue damage is a result of a dynamic process in which normal cells actively play a role, and that the interaction between different cell groups results in fibrosis.^{4,26)} The hypothesis that radiation-induced pulmonary fibrosis might be prevented by treating the cellular dysfunction of parenchymal or vascular cells, which is observed in chronic inflammation, or by avoiding the chronic increase observed in specific cytokines and growth factors was the starting point for the present, as it was for many other studies. In the present study the effect of vitamin D3 in preventing radiation-induced pulmonary toxicity in rats given a single dose of 20-Gy radiotherapy was examined. Light microscopy revealed no significant dif-

ference between the irradiation only (group 3) and irradiation + vitamin D (group 4) groups; however, electron microscopy findings showed that the signs of radiation-induced pulmonary toxicity were significantly less severe in group that received irradiation + vitamin D.

The first study to examine the role of vitamin D in preventing radiation-induced pulmonary toxicity was performed by Graham *et al.*¹¹⁾ They proposed that the mechanisms involved in radiation-induced pulmonary toxicity might be similar to those involved in idiopathic pulmonary fibrosis, and they treated rats given pulmonary radiotherapy with vitamin D, dexamethasone, and indomethacin, separately. They reported that in the rats given 18-Gy left hemithorax radiotherapy, vascular permeability increased significantly in the third week, and that dexamethasone, vitamin D, and indomethacin prevented radiation-induced vascular permeability.¹¹⁾

In our study light microscopy findings revealed no differences between the groups at any time point; however, electron microscopic evaluations showed that vitamin D reduced the damage in type II pneumocytes, reduced interstitial inflammation, collagen bundle deposition, and fibrosis, and prevented the narrowing of the alveolar space and deposition of exudates in the alveolar space. The decrease in the inflammatory cell accumulation in the perivascular space in response to vitamin D, which is a sign of a decrease in vascular permeability, is consistent with Graham *et al.*¹¹⁾

It was reported that the effect of radiotherapy on type II pneumocytes could be observed in the first 24 h with electron microscopy and that fibrotic changes occurred in the following 1–3 months.¹⁹⁾ In the present study fibrotic changes were apparent in the eighth week. In the group that received irradiation alone increased eosinophil and mast cell accumulation in the perivascular field, destruction of epithelial cells that line the alveoli and shedding of those cells to the alveolar space, serous fluid accumulation and bleeding in the alveolar space, connective tissue accumulation, increased cell infiltration and fibrocytes, accumulation of collagen bundles in the interstitial space, and narrowing of the alveolar space was observed. In irradiation + vitamin D group it was observed that the cells that line the alveoli were not destroyed, there was no narrowing of the alveolar space, and no debris or accumulation of exudates was observed in the alveolar space. The cells were not degenerated and were healthier when compared to irradiation only group. We also observed a significant decrease in inflammatory cell and collagen bundle accumulation in the interstitial space. Vitamin D injections were stopped after 8 weeks; however, at the twelfth week the protective effect of vitamin D could still be observed. At the twelfth week it was observed in irradiation only group that inflammatory cell accumulation continued, collagen bundles were organized, and fibrosis was observed in the interstitial space. In irradiation + vitamin D group however, cell degeneration, interstitial inflammation, and collagen accumulation or fibrosis were not prominent. The

cells and the ultra structure of the lungs were healthier when compared to irradiation only group; however, no apparent difference between the groups could be found with light microscopy evaluation. This discrepancy between the light and electron microscopy findings may have been a result of the grading system that was used for light microscopy. The grading system of 0–3 may not have been enough to detect small differences. Generally, studies based on light microscopy reported that fibrotic changes could be observed after 6 months, though there are studies in the literature that reported observing fibrosis 12 weeks after radiotherapy.²⁷⁾ In our study all the rats were sacrificed and examined 12 weeks after radiotherapy. We think that it might have been possible to detect differences between groups that received irradiation alone and irradiation + vitamin D with light microscopy had we waited longer.

Vitamin D has antineoplastic effects against several cancer types.^{6,7,9)} Besides its antineoplastic effect it also increases the radiosensitivity of the cancer cells by inducing apoptosis, inhibiting the progression of the cell through the cell cycle and causing cell arrest at G1/S and G2/M phases (radiosensitive phases), inhibiting cell proliferation, and inducing the differentiation of the cells.^{7,10,28–30)} The radiosensitizer effect of vitamin D is selective. It has no such effect on normal fibroblasts and keratinocytes.^{10,31)} In kidneys vitamin D inhibits the transformation of fibroblasts to myofibroblasts which is induced by TGF β -1.¹²⁾ In skin it inhibits the proliferation of fibroblasts.¹³⁾ The clinic observation of reduction in the size of an aggressive fibromatosis mass resistant to surgery, radiotherapy, and tamoxifen under vitamin D treatment caused a speculation that vitamin D may have a role in the degradation of collagen.^{15,32)} To evaluate the molecular mechanisms of vitamin D's anticancer, selective radiosensitizer, and antifibrotic effects is beyond the aim of this study. However a radioprotector which also has antineoplastic effects is an appealing treatment modality for radiation oncologists and can be used to increase the therapeutic ratio in the treatment of various tumor types. We suggest, whether vitamin D fits in this category should be evaluated with further studies.

In conclusion, the present study revealed that vitamin D may have a potential beneficial effect in the prevention of radiation-induced pneumonitis and pulmonary fibrosis. We recommend that clinical studies be conducted to confirm these experimental findings.

ACKNOWLEDGEMENTS

FUNDING SOURCE: Supported by Hacettepe University. (HUTF 06D01-101-006)

There is no role of study sponsors in the study design, in the collection, analysis and interpretation of data; in the writing of the manuscript; and in the decision to submit the manuscript for publication.

REFERENCES

1. Finkelstein JN, *et al* (1994) Early alterations in extracellular matrix and transforming growth factor beta gene expression in mouse lung indicative of late radiation fibrosis. *Int J Radiat Oncol Biol Phys* **28**: 621–631.
2. Rubin P, *et al* (1995) A perpetual cascade of cytokines postirradiation leads to pulmonary fibrosis. *Int J Radiat Oncol Biol Phys* **33**: 99–109.
3. Martinet Y, *et al* (1996) Cytokines in human lung fibrosis. *Arch Toxicol Suppl* **18**: 127–139.
4. Martin M, Lefaix JL and Delanian S (2000) TGF β 1 and radiation fibrosis: a master switch and a specific therapeutic target? *Int J Radiat Oncol Biol Phys* **47**: 277–290.
5. Abe E, *et al* (1981) Differentiation of mouse myeloid leukemia cells induced by 1,25-dihydroxyvitamin D₃. *Proc Natl Acad Sci USA* **78**: 4990–4994.
6. Akther J, Goerdel M and Morris DL (1996) Vitamin D₃ analog (EB1089) inhibits in vitro cellular proliferation of human colon cancer cells. *Br J Surg* **83**: 229–230.
7. Polar MK, *et al* (2003) Effect of vitamin D₃ analog ILX 23-7553 on apoptosis and sensitivity to fractionated radiation in breast tumor cells and normal human fibroblasts. *Cancer Chemother Pharmacol* **51**: 415–421.
8. Freedman LP (1999) Transcriptional targets of the vitamin D₃ receptor-mediating cell cycle arrest and differentiation. *J Nutr* **129**: 581S–586S.
9. Beer TM and Myrthue A (2004) Calcitriol in cancer treatment: from the lab to the clinic. *Mol Cancer Ther* **3**: 371–381.
10. Dunlap N, *et al* (2003) 1 α , 25-dihydroxyvitamin D₃ (calcitriol) and its analogue, 19-nor-1 α , 25-(OH)₂D₂, potentiate the effects of ionising radiation on human prostate cancer cells. *Br J Cancer* **89**: 746–753.
11. Graham MM, *et al* (1990) Pharmacological alteration of the lung vascular response to radiation. *Int J Radiat Oncol Biol Phys* **19**: 329–339.
12. Li Y, *et al* (2005) 1,25-dihydroxyvitamin D inhibits renal interstitial myofibroblast activation by inducing hepatocyte growth factor expression. *Kidney Int* **68**: 1500–1510.
13. Muller K, *et al* (2006) 1 α , 25-Dihydroxyvitamin D₃ modulates the response of human keratinocytes to ionizing radiation exposure. *Anticancer Res* **26**: 2735–2741.
14. McCarthy DM, Hibbin JA and Goldman JM (1984) A role for 1,25-dihydroxyvitamin D₃ in control of bone-marrow collagen deposition? *Lancet* **1**: 78–80.
15. Yildiz F, *et al* (2004) Possible therapeutic role of vitamin D₃ in aggressive fibromatosis. *Jpn J Clin Oncol* **34**: 472–475.
16. Nonn RA and Gross NJ (1996) Effects of radiation on the lung. *Curr Opin Pulm Med* **2**: 390–395.
17. Marks LB (1994) The pulmonary effects of thoracic irradiation. *Oncology (Williston Park)* **8**: 89–106.
18. McDonald S, *et al* (1995) Injury to the lung from cancer therapy: clinical syndromes, measurable endpoints, and potential scoring systems. *Int J Radiat Oncol Biol Phys* **31**: 1187–1203.
19. Movsas B, *et al* (1997) Pulmonary radiation injury. *Chest* **111**: 1061–1076.
20. Roach M 3rd, *et al* (1995) Radiation pneumonitis following combined modality therapy for lung cancer: analysis of prognostic factors. *J Clin Oncol* **13**: 2606–2612.
21. Shapiro DL, *et al* (1982) Sequential effects of irradiation on the pulmonary surfactant system. *Int J Radiat Oncol Biol Phys* **8**: 879–882.
22. Rubin P, *et al* (1980) The early release of surfactant following lung irradiation of alveolar type II cells. *Int J Radiat Oncol Biol Phys* **6**: 75–77.
23. Ward WF, *et al* (1983) Radiation injury in rat lung. II. Angiotensin-converting enzyme activity. *Radiat Res* **96**: 294–300.
24. Ts'ao CH, Ward WF and Port CD (1983) Radiation injury in rat lung. III. Plasminogen activator and fibrinolytic inhibitor activities. *Radiat Res* **96**: 301–308.
25. Haffner D, *et al* (2005) Systemic cardiovascular disease in uremic rats induced by 1,25(OH)₂D₃. *J Hypertens* **23**: 1067–1075.
26. Morgan GW and Breit SN (1995) Radiation and the lung: a reevaluation of the mechanisms mediating pulmonary injury. *Int J Radiat Oncol Biol Phys* **31**: 361–369.
27. Abdollahi A, *et al* (2005) Inhibition of platelet-derived growth factor signaling attenuates pulmonary fibrosis. *J Exp Med* **201**: 925–935.
28. Sundaram S, *et al* (2000) EB 1089 enhances the antiproliferative and apoptotic effects of adriamycin in MCF-7 breast tumor cells. *Breast Cancer Res Treat* **63**: 1–10.
29. Gewirtz DA, Gupta MS and Sundaram S (2002) Vitamin D₃ and Vitamin D₃ analogues as an adjunct to cancer chemotherapy and radiotherapy. *Curr Med Chem Anticancer Agents* **2**: 683–690.
30. Narvaez CJ, Zinser G and Welsh J (2001) Functions of 1 α , 25-dihydroxyvitamin D(3) in mammary gland: From normal development to breast cancer. *Steroids* **66**: 301–308.
31. Trémezaygues L, *et al* (2010) 1,25-dihydroxyvitamin D₃ modulates effects of ionizing radiation (IR) on human keratinocytes: in vitro analysis of cell viability/proliferation, DNA-damage and -repair. *J Steroid Biochem Mol Biol* **121**(1-2): 324–327.
32. Yildiz F, *et al* (2005) 1,25-Dihydroxy vitamin D₃: can it be an effective therapeutic option for aggressive fibromatosis. *Med Hypotheses* **64**(2): 333–336.

Received on March 4, 2011

Revision received on May 17, 2011

Accepted on May 25, 2011