


Journal Pre-proof

EL PAPEL DE LA TERAPIA ADYUVANTE EN EL TRATAMIENTO DE LA URTICARIA CRÓNICA ESPONTÁNEA

W Keumala Budianti S Mahri D Almira



PII: S0001-7310(23)00171-0

DOI: <https://doi.org/doi:10.1016/j.ad.2023.02.015>

Reference: AD 3417

To appear in: *Actas dermosifiliograficas*

Received Date: 16 October 2022

Accepted Date: 25 February 2023

Please cite this article as: Budianti WK, Mahri S, Almira D, EL PAPEL DE LA TERAPIA ADYUVANTE EN EL TRATAMIENTO DE LA URTICARIA CRÓNICA ESPONTÁNEA, *Actas dermosifiliograficas* (2023), doi: <https://doi.org/10.1016/j.ad.2023.02.015>

This is a PDF file of an article that has undergone enhancements after acceptance, such as the addition of a cover page and metadata, and formatting for readability, but it is not yet the definitive version of record. This version will undergo additional copyediting, typesetting and review before it is published in its final form, but we are providing this version to give early visibility of the article. Please note that, during the production process, errors may be discovered which could affect the content, and all legal disclaimers that apply to the journal pertain.

© 2023 Published by Elsevier.

Sección. revisión

EL PAPEL DE LA TERAPIA ADYUVANTE EN EL TRATAMIENTO DE LA URTICARIA CRÓNICA ESPONTÁNEA

THE ROLE OF ADJUVANT THERAPY IN THE MANAGEMENT OF CHRONIC URTICARIA

W. Keumala Budianti, S. Mahri, D. Almira

Department Dermatology and Venereology of Faculty of Medicine Universitas Indonesia,

Dr. Cipto Mangunkusumo Jakarta

Corresponding author: donnalmira19@gmail.com

Journal Pre-proof

RESUMEN

Las directrices actuales para el tratamiento de la urticaria crónica recomiendan los antihistamínicos H1 de segunda generación como tratamiento de primera línea, con un aumento de hasta cuatro veces la dosis si no se controla. Sin embargo, la terapia en la urticaria crónica espontánea suele ser decepcionante, por lo que es necesario un tratamiento adyuvante adicional para mejorar la eficacia de la terapia, especialmente en los pacientes que son refractarios a dosis mayores de antihistamínicos. Las investigaciones más recientes recomiendan varias modalidades de tratamiento adyuvante para la urticaria crónica espontánea, como los agentes biológicos, los inmunosupresores, los antagonistas de los receptores de leucotrienos, los antihistamínicos H2, las sulfonas, la terapia con suero autólogo, la fototerapia, la vitamina D, los antioxidantes y los probióticos.

Esta revisión bibliográfica presenta estudios recientes sobre la eficacia de diversas terapias adyuvantes en el tratamiento de la urticaria crónica espontánea.

Palabras clave: urticaria crónica espontánea, terapia adyuvante, terapia complementaria

ABSTRACT

Recent guideline on the management of urticaria recommends second-generation H1-antihistamine as the first-line therapy, with dose increases of up to fourfold if inadequately controlled. However, the treatment of chronic spontaneous urticaria (CSU) is often disappointing, so additional adjuvant therapies are needed to increase the effectiveness of first-line therapy, especially in patients who are refractory to the increase of antihistamine doses. Recent studies recommend various adjuvant therapy modalities for CSU, such as biological agents, immunosuppressants, leukotriene receptor antagonists, H2-antihistamine, sulfones, autologous serum therapy, phototherapy, vitamin D, antioxidants, and probiotics. This literature review was made to determine the effectiveness of various adjuvant therapies in managing CSU.

Keywords: chronic spontaneous urticaria, adjuvant therapy, complementary therapy

INTRODUCTION

Nowadays, second generation of H1 antihistamine as the first line therapy is recommended by the recent management of urticaria guidelines with an increase in dosage 4 times higher when there is no improvement in the clinical symptoms.¹ Despite the dosage enhancement, chronic spontaneous urticaria (CSU) therapy still requires a complement agent to maximize its effect, necessitating the use of adjuvant therapy to increase the effectiveness of the first line therapy. Adjuvant therapy for CSU is needed, especially for refractory patients receiving increased antihistamine doses. This literature review will discuss further a variety of adjuvant therapy and their role in the management of CSU. As shown in the **Table 1**, the level of evidence (LoE) of the management is based on Oxford Center for Evidence-Based Medicine 2011 for the therapeutic study and the simplified table of adjuvant therapy modalities can be seen in the **Table 2**.

CHRONIC SPONTANEOUS URTICARIA

The goal of treating CSU is to resolve all symptoms through non-pharmacology approaches, including identification and elimination of the urticaria causes, avoiding trigger factors, and tolerance induction; then pharmacological therapy to prevent the release of mast cell mediators or the effect of mast cell mediators. The pharmacological treatment should allow the lowest dose to alleviate the symptoms. The treatment is adjustable, corresponding to the degree of disease activity.² As illustrated in **Figure 1**, EAACI/GA2LEN/EDF/WAO guideline in 2022 recommends the second generation of H1 antihistamine to be the first line of therapy for CSU, with the dosage enhancement up to 4 times higher if there is no improvement in the clinical symptoms.¹

ADJUVANT THERAPY FOR CHRONIC SPONTANEOUS URTICARIA

Adjuvant therapy is an additional therapy that is given together with the first line therapy simultaneously with the purpose of increasing the therapy effectivity.⁸ Adjuvant therapy in CSU is needed primarily on patients with no response to the treatment or refractory towards increasing antihistamine doses. The following sections will discuss several adjuvant therapies and their roles in CSU.

Biologic Agent

Biological agent comes from living things and is used to prevent, diagnose, or treat a disease. The biologic agents used to treat chronic refractory urticaria are omalizumab, rituximab, intravenous immunoglobulin (IVIg), dan inhibitor TNF- α (infliximab, adalimumab, and etanercept); all used alongside the standard antihistamine regimen.⁵

1. Omalizumab

Omalizumab (OMA) is a recombinant monoclonal antibody that comes from a human and acts as an anti-IgE antibody, preventing the binding of IgE to receptor cells.^{9,10} The effectiveness of OMA is proven and well tolerated in patients with refractory CSU. The EAACI/GA2LEN/EDF/WAO guidelines in 2022 recommend OMA as the third-line therapy for patients with chronic refractory urticaria towards the increase of H1 antihistamine dosage.²

The mechanism of action of OMA is not fully understood. Kaplan et al have reported the mechanism of actions of OMA in the CSU treatment is by decreasing the free IgE and IgE receptors, reducing the mast cell ability to release histamine, restoring basopenia, restoring the IgE receptors function in basophile, reducing the activity of auto-antibody IgG towards IgE and its receptors, reducing the abnormal IgE

intrinsic activity, reducing the auto-antibody IgE towards an antigen or an unknown auto-antigen, and reducing abnormal coagulation which related to the disease activity through in vitro.¹¹

The effectivity of the OMA addition in the CSU treatment was reported in many phases II^{12,13} and phase III¹⁴⁻¹⁶ clinical trials, as well as meta-analysis.¹⁷ The three phase III clinical trials observed CSU/CindU moderate-severe patients who did not respond to the standard treatment and other additional therapies were given OMA 75 mg, 150 mg, or 300 mg for 12-24 weeks, and there was a decrease in the itch severity score (ISS) on the 12-week treatment. Casale et al¹⁸ have reported that there were more patients with urticaria activity score 7 (UAS7) ≤ 6 (symptoms are well controlled) or UAS7 0 (symptoms are perfectly controlled) when treated with OMA 300 mg compared to placebo.

OMA is effective in the dosage of 150-300 mg per month. The dosage and duration of the therapy may vary between countries. Generally, OMA is well tolerated, and the most common side effects are nasopharyngitis, sinusitis, URTI, headache, and cough.¹⁸ The risk of anaphylactic may occur two hours after the first administration of OMA; thus, careful observation is needed.¹⁸

2. Rituximab

Rituximab is a chimeric monoclonal antibody to CD20. The mechanism of action of rituximab in CSU prevents the production of autoantibody.¹⁹ The rituximab treatment result varies widely. A case report of a patient with pressure urticaria who failed in the first and second line of therapy had received rituximab 375 mg/m²/week infusion 4 times; however, there was no improvement. A case report of CSU and immunodeficiency treated by rituximab 375 mg/m²/week, 4 times, showed a perfect recovery of urticaria symptoms within 1 week, with remission of more than 1 year, and later the symptoms will be easily treated by an antihistamine.²⁰ Another case report of refractory autoimmune CSU was given rituximab per week (4 times in dosage, within 4 weeks) along with the administration of methotrexate showed a perfect remission 6 weeks after the last administration.²¹ There was no randomized controlled trials (RCT) study of rituximab in CSU.

3. Inhibitor TNF- α

Some TNF- α inhibitors drugs such as etanercept, infliximab, and adalimumab were used to treat CSU or vasculitis urticaria based on the postulation that TNF may have important roles in some types of urticaria.^{22,23} For example, etanercept 2x25 mg/week is useful to treat delayed pressure urticaria and psoriasis. On the 5-day of treatment, the urticaria was resolved and did not appear until the end of the therapy.²⁴ A case series of 6 patients with chronic idiopathic urticaria or vasculitis urticaria treated by inhibitor TNF- α showed a dramatic clinical improvement in all patients.²⁵

Serious infections such as tuberculosis, fungal infection, lymphoma, and malignancy were reported. This drug is not recommended for CSU treatment due to its lack of evidence to support the safety and efficacy of the treatment. Furthermore, there is no clinical trial comparing this drug to OMA, in which the safety and efficacy have been tested.

Immunosuppressant

1. Cyclosporin

A low dose of cyclosporin is commonly used in severe and refractory CSU/CindU patients. The EAACI/GA2LEN/EDF/WAO guidelines in 2022 recommend the use of cyclosporin as the fourth line therapy in a patient with CSU resistant to H1 antihistamine and OMA. Cyclosporin acts as an immunosuppressant which effect is known to attenuate T cell activity. In CSU, cyclosporin has a role in some mechanisms, such as calcineurin inhibitors, which hinder the calcium-dependent release by histamine, C4 leukotriene, and other mast cell mediators and several other cells. Cyclosporin also disrupts the TNF- α activity and secondarily inhibits neutrophile accumulation.²⁶

A systematic review in 2018 showed a significant improvement in urticaria symptoms in CSU patients who were given a relatively high dose cyclosporin (5-6 mg/kg/day). However, the patient usually stops the therapy due to the occurrence of side effects. The majority of new studies use a lower dose (2–4 mg/kg/day) or an initial therapy with a high dose to continue tapering down the dose to get the lowest effective dose.²⁶ Studies done in the pediatric population also use a low range of doses. Randomized clinical trials involving CSU refractory patients resistant to standard antihistamine compared a group receiving 4 mg/kg/day cyclosporin and a group receiving a placebo for 4 weeks. Eight out of 19 (42%)

patients receiving cyclosporin showed an improvement compared to placebo. Mild side effects were observable in 29 out of 30 subjects.²⁷

There is still no guideline for the optimal cyclosporin dose in CSU. The last systematic review recommends the initial therapy with 3 mg/kg cyclosporin, divided into 2 doses. The majority of adult patients were given the dosage of 100 – 150 mg, 2 times per day. Some of the patients showed improvement in 1-2 weeks, whilst most other patients showed improvement within 3 months.²⁶ As for the mild side effects of cyclosporin use (dosage related) are paresthesia, gastrointestinal symptoms, and headache. The dosage reduction may subside the symptoms. Hypertension and kidney insufficiency is a severe and uncommon side effect indicating the termination of the therapy.²⁶

2. Methotrexate

Several case reports and case series have reported the effectiveness of methotrexate in reducing the symptoms of CSU patients with steroid dependence^{28,29} and vasculitis urticaria.³⁰ An RCT in India concluded that the addition of methotrexate (7.5-15 mg per week) for 3 months in chronic refractory urticaria did not show any significant benefit.³¹ Although available data is still limited, several studies recommend methotrexate as the alternative therapy in some refractory urticaria cases, mainly due to its affordable price, availability, schedule-friendly, and wide acceptance.

3. Mycophenolate Mofetil

Mycophenolate mofetil (MMF) is an immunomodulator agent to treat solid-organ transplant rejection and several dermatosis conditions (off-label). The mechanism of MMF immunomodulator in chronic autoimmune and idiopathic urticaria is not fully known. MMF is known to be effective in the urticaria treatment by inhibiting the autoantibody production towards high affinity of IgE receptors and/or IgE, as well as reducing the adhesion molecule expression to endothelial cells, thus inhibiting the leucocyte invasion to the skin.³⁵

In a clinical study of 9 refractory CSU patients resistant to antihistamine and/or steroids, the

administration of 2x1000mg MMF for 12 weeks reduced the UAS score and curbed the disease activity even without steroids.³² A retrospective study of 19 patients with autoimmune urticaria and chronic idiopathic urticaria showed 89% controlled urticaria symptoms for 14 weeks of MMF consumption (dosed at 1000-6000 mg/day, in divided dosage). However, it was reported that the most common side effects are gastrointestinal symptoms.³³ Nevertheless, due to lack of scientific evidence, doubtful effect, high price, and side effects reported, MMF is not recommended to be used as a treatment in the guideline for CSU/CindU patients.

Leukotriene Receptor Antagonists (LTRA)

In most, CSU treatment is hard to be controlled only with antihistamines. Therefore, a suspicion of other mediators which have a role other than histamines, such as kinin, prostaglandin, and leukotriene, which may be responsible for some of the urticaria symptoms which cannot be controlled with antihistamine. Cysteinyl leukotrienes is a potent pro-inflammatory mediator which can be inhibited by LTRA like montelukast, zafirlukast, and pranlukast.³⁶ The use of these drugs in asthma and allergy rhinitis is already proven beneficial. CSU guidelines by the British Society for Allergy and Clinical Immunology (BSACI) and The American Consensus Document recommends the addition of LTRA before prescribing OMA and cyclosporin.

A systematic review by De Silva et al³⁶ suggested a reduction in the urticaria lesion number in patient with LTRA monotherapy compared to placebo. The combination of antihistamine and LTRA is proven to be beneficial in many studies even though there was one study that showed contradictive findings. Generally, some of the most recent studies supported LTRA in combination with antihistamine, and the effect of additional LTRA in patients with antihistamine therapy showed beneficial results when prescribed 10 mg/day for 2-4 weeks. One of the weaknesses of LTRA therapy is the price that is more expensive for one month of therapy compared to the antihistamine within the same time range. However, as a combination therapy with antihistamine, LTRA showed a good tolerance with minimal side effect.³⁶

Antihistamin H2

H2 Antihistamine is a class of drugs binding to H2 histamine receptors which are commonly found in stomach cells. H2 antihistamine is clinically used in acid-related gastrointestinal conditions therapy such as peptic ulcer, gastroesophageal reflux (GERD), and dyspepsia. H2 antihistamine is also used in urticaria

therapy; generally, it is combined with H1 antihistamine. Several drugs in this class are cimetidine, ranitidine, famotidine, roxatidine, lafutidine, and nizatidine.

A systematic review concluded that the combination of H1 antihistamine and H2 antihistamine in a patient with CSU showed a clinical improvement compared to H1 antihistamine alone, even though the level of evidence is still minimal.⁶² The synergism between H1 antihistamine and H2 antihistamine is still debatable; however, the possible cause may relate to its pharmacokinetic effect in which H2 antihistamine caused the level of H1 antihistamine in the plasma to increase. An RCT in 45 CSU patients receiving terfenadine and ranitidine as an adjuvant showed a better result compared to the administration of terfenadine only, mostly to reduce the itchy complaint; however, there was no significant effect on the urticaria symptoms.⁶³

Majority RCT and some case reports showed that adding H2 antihistamine still provides insufficient benefits; moreover, it did not meet the expectations of some studies.⁶² Therefore, this drug is not included in the primary treatment of CSU based on EAACI/GA2LEN/EDF/WAO guidelines in 2022. Generally, H2 antihistamine can be well tolerated. Some side effects reported were hypotension, headache, dizziness, diarrhea, rash, gynecomastia, loss of libido, and impotency.

Sulfone

Dapsone and sulfasalazine have been used in several studies as adjunctive therapy for CSU cases.⁴⁵

1. Dapsone

Dapsone worked by suppressing prostaglandin and leukotriene activity, influencing the release or function of neutrophil lysosomal enzymes,³⁷ interfering with integrin-mediated neutrophil adhesion, inhibition of neutrophil recruitment, and signal activation,³⁸ as well as removing oxygen-free radical intermediates.³⁹

A RCT study consisting of 22 CSU patients treated with dapsone 100mg/day for 6 weeks has been shown to have good results in controlling urticaria and itching symptoms.⁴⁰ A RCT reported that the combination of dapsone with antihistamines compared to single antihistamine use shown to have a decrease in UAS scores with complete remission in some cases.⁴¹ Furthermore, dapsone is effective in treating urticaria vasculitis and idiopathic angioedema.⁴²⁻⁴⁴

Side effects of dapsone include methemoglobinemia, peripheral neuropathy, and hepatotoxicity. Therefore it is necessary to check for G6PD deficiency before starting treatment. Due to the limited availability of scientific evidence and the possibility of serious side effects, the EAACI/GA2LEN/EDF/WAO 2022 guidelines do not recommend the use of dapsone as therapy for CSU/CindU.⁴⁵

2. Sulfasalazine (SSZ)

The mechanism of action of SSZ in CSU patients includes the release of adenosine, reduced synthesis of leukotrienes and prostaglandins, inhibition of IgE-mediated Mast cell degranulation, also inhibition of early-phase proliferation and differentiation of B lymphocytes.⁴⁶

Studies have concluded that sulfasalazine is useful as an adjunct to standard therapy for patients with refractory symptoms.^{46,47} A retrospective study of 39 patients with refractory CSU towards antihistamines and other therapies were given sulfasalazine as an adjunct therapy, with an initial dose of 500mg per day, then increased per week up to 2000mg per day (and up to 3000 mg per day in 15 patients) if tolerated.⁴⁶ 84% of patients had improvement within 3 months, with a mean duration of therapy of 74 weeks.

In adults, sulfasalazine therapy can be started at a dose of 500mg, 1-2 times per day, and increased gradually to 1 gram, twice daily. The optimal duration of therapy varies from individual to individual. In general, sulfasalazine is well tolerated in the majority of patients. Side effects include nausea, headache, mild and transient leukopenia, and to a lesser degree agranulocytosis.

Phototherapy

Phototherapy using psoralen with ultraviolet A (PUVA) or narrow band UVB (NB-UVB) and UVA is beneficial in CSU.^{49,50} Phototherapy is also considered a treatment option in patients with intolerance to systemic drugs. The skin directly exposed to ultraviolet radiation experienced dramatic improvement; this is the basis for the assumption that there are mediators and local cells that act as primary targets.⁵¹ Although the effectiveness of NB-UVB in CSU has been suggested in several studies, the exact mechanism of NB-UVB in CSU is still unclear. NB-UVB has a suppressive effect on systemic immune response and natural killer (NK) cell activity, lymphocyte proliferation, and regulation of cytokine production by TH1 (IL-2, IFN- γ) and Th2 (IL-10). NB-UVB also has an inhibitory effect on proinflammatory mediators and cytokines.

A systematic review concluded that NB-UVB is an adjuvant therapy modality in the management of refractory CSU.⁴⁸ A RCT of 50 CSU patients refractory to H1 antihistamines and oral steroid-dependent

patients compared the administration of NBUV and PUVA. There was greater clinical improvement in the group with NBUVB than in the PUVA group. Side effects only occur in a small number of patients, including tanning and xerosis.⁵²

A study by Sheikh et al⁵³ shows that NBUVB can be an effective adjuvant therapy with antihistamines in patients with CSU. The combination allows a greater reduction in UAS than single antihistamine use. In this study, the initial dose of phototherapy started at 200 mJ/cm² in 16 sessions over 8 weeks. Berroeta et al⁵⁴ reported that the median of phototherapy sessions in CSU patients was 22 sessions, the frequency being 3x/week with an initial dose of 70%, starting with the minimum erythema dose then increased by 10-20% per visit, and a media dose of 1238 mJ/cm² (range 100-2111 mJ/cm²). Meanwhile, Engin et al^{55,56} suggested that the number of therapy was 20 sessions, with a frequency of 3x/week and an initial dose of 200 mJ/cm², increased by 10-20% to a maximum dose of 1300 mJ/cm². The side effects of NBUVB therapy include erythema, pruritus, and vesiculation.⁵³

Autologue Serum Therapy

Approximately 30-50% of patients with CSU have autoantibodies binding to the high-affinity IgE receptor FcεR1α on basophils or mast cells that produce histamine and IgE.⁵⁷ Hide et al⁵⁸ reported that intracutaneous injection of serum, the autologous serum skin test (ASST), causes a type of rapid hypersensitivity reaction in patients with CSU, which is referred to as autoreactive or autoimmune CSU. These patients had scores of itching or urticaria and more severe systemic symptoms associated with other autoimmune diseases. Because circulating histamine-releasing factors play a role in the induction of urticarial symptoms in ASST-positive CSU patients, autohemotherapy is considered promising and has potential as a treatment option in chronic autoimmune urticaria.

A systematic review by Chang et al⁶⁵ in 2019 concluded that autologous whole blood (AWB) and autologous serum therapy (AST) were not significantly more effective in relieving CSU symptoms than placebo. Nageswaramma et al.⁵⁹ reported 50 CSU patients with positive and negative ASST were given autologous serum therapy (AST) injections weekly for 9 weeks and followed for 12 weeks after 9 weeks of injections. Urticaria symptoms decreased at week 4, and antihistamine use decreased 100% from baseline in both groups. The patient was found to be in complete remission at week 21.

In a study by Kumaravel et al⁶⁰, involving 200 CSU patients, AST was intramuscularly administered to 47

ASST (+) patients every week for 9 weeks and followed for 3 months. At the end of therapy, none of the patients had severe TSS, 9 patients were symptom-free, and the majority had only mild TSS. As reported by Karn et al,⁶¹ 102 patients with CSU patients with both ASST (+) and (-), an intramuscular injection of 0.05 ml/kg autologous serum was administered weekly for 10 weeks. There was a significant improvement in UAS at week 10 compared to baseline in both groups. In patients with chronic autoimmune urticaria, ASST is an inexpensive, effective therapeutic modality with minimal side effects.

Vitamin D

Vitamin D plays an important role in the innate and adaptive immune systems through stimulation of Toll-like receptors, increasing production of pro-inflammatory cytokines, and possibly enhancing the T helper 2 response. This mechanism may explain the association of vitamin D with several autoimmune allergic diseases, including CSU.⁵

A systematic review by Tuchinda et al⁶² stated that high-dose vitamin D supplementation could significantly reduce CSU activity. Another study stated that vitamin D supplementation of 2000 IU/day and 60,000 IU/week reduced disease activity in almost all CSU patients. Of the various regimens, higher doses of vitamin D (Vitamin D3 at least 28,000 IU/week for 4-12 weeks or vitamin D2 140,000 IU/week for 6 weeks) were reported to be more effective. Although studies are relatively sparse, CSU patients with low serum vitamin D at study entry tend to improve with high-dose vitamin D supplementation. Vitamin D has a high safety dose limit. The maximum tolerable intake is 4000-10,000 IU/day for adults and the elderly but lower for infants and children.

Although there are no reports of side effects during administration of vitamin D therapy, patient safety should be considered when using high doses of vitamin D. Assessment of serum vitamin D levels can be used to evaluate the safety and determine the relationship to therapeutic outcomes, and caution should be exercised regarding potential side effects when serum 25(OH)D levels are more than 50 ng/ml(125nmol/l). In recalcitrant CSU patients with low serum vitamin D levels, high-dose vitamin D supplementation for 4-12 weeks can be used as adjuvant therapy.

CONCLUSION

Omalizumab become the first adjuvant therapy option, however in some countries omalizumab is still not available and accessible. Other reasons are cost-effectiveness (omalizumab is high in price) and not covered by government health insurance. Patients need to be assessed comprehensively prior choosing the treatment. Phototherapy is one of the alternative treatment considering its mild side effects, however it shows lack in patient adherence, therefore systemic therapy is recommended such as methotrexate and other agents.

Several adjuvant therapy modalities in CSU can act synergically to increase the effectivity of the first line therapy, which is H1 antihistamine second generation in CSU treatment. Further investigation is required to evaluate adjuvant therapy modalities with a better and more consistent method so, it can improve the clinical practice.

Journal Pre-proof

REFERENCE

1. Michihiro H, Shunsuke T, Takaaki H. Urticaria and angioedema. Dalam: Sewon K, Masayuki A, Anna L B, Alexander H E, David J M, Amy J MM, et al., editors. Fitzpatrick's Dermatology. ed 9. New York: McGraw-Hill Education; 2019. hal. 685–704.
2. Zuberbier T, Abdul Latiff AH, Abuzakouk M, et al. The international EAACI/GA²LEN/EuroGuiDerm/APAAACI guideline for the definition, classification, diagnosis and management of urticaria. *Allergy*. 2022;77:734–766.
3. Deacock SJ. An approach to the patient with urticaria. *Clin Exp Immunol*. 2008;153(2):151–61.
4. Zuberbier T, Balke M, Worm M, Edenharter G, Maurer M. Epidemiology of urticaria: a representative cross-sectional population survey. *Clin Exp Dermatol*. 2010;35(8):869–73.
5. Bernstein JA, Lang DM, Khan DA. The diagnosis and management of acute and chronic urticaria: 2014 update. *J Allergy Clin Immunol*. 2014;133(5):1270–7.
6. Wertenteil S, Strunk A, Garg A. Prevalence estimates for chronic urticaria in the United States: A sex- and age-adjusted population analysis. *J Am Acad Dermatol*. 2019 Jul;81(1):152–6.
7. Schaefer P, College T, Sciences L. Acute and chronic urticaria: Evaluation and treatment. *Am Fam Physician*. 2017;95(11):717–24.
8. KBBI, 2020. Kamus Besar Bahasa Indonesia (KBBI). [Online] Available at: <https://kbbi.web.id/adjuvan> [Diakses 20 Maret 2020].
9. Normansell R, Walker S, Milan SJ, Walters EH, Nair P. Omalizumab for asthma in adults and children. *Cochrane Database Syst Rev*. 2014;1:CD003559.
10. Easthope S, Jarvis B. Omalizumab. *Drugs*. 2001;61(2):253-60.
11. Kaplan AP, Gimenez-Arnau AM, Saini SS. Mechanism of action that contribute to efficacy of omalizumab in chronic spontaneous urticaria. *Allergy*. 2016.
12. Saini S, Rosen KE, Hsieh HJ, et al. A randomized, placebo-controlled, dose-ranging study of single-dose omalizumab in patients with H1-antihistamine-refractory chronic idiopathic urticaria. *J Allergy Clin Immunol*. 2011;128(3):56773.e1.
13. Maurer M, Altrichter S, Bieber T, et al. Efficacy and safety of omalizumab in patients with chronic urticaria who exhibit IgE against thyroperoxidase. *J Allergy Clin Immunol*. 2011;128(1):202-9e5.
14. Maurer M, Rosen K, Hsieh HJ, et al. omalizumab for the treatment of chronic idiopathic or spontaneous urticaria. *N Engl J Med*. 2013;368(10):924-35.
15. Kaplan A, ledford D, Ashby M, et al. Omalizumab in patients with symptomatic chronic

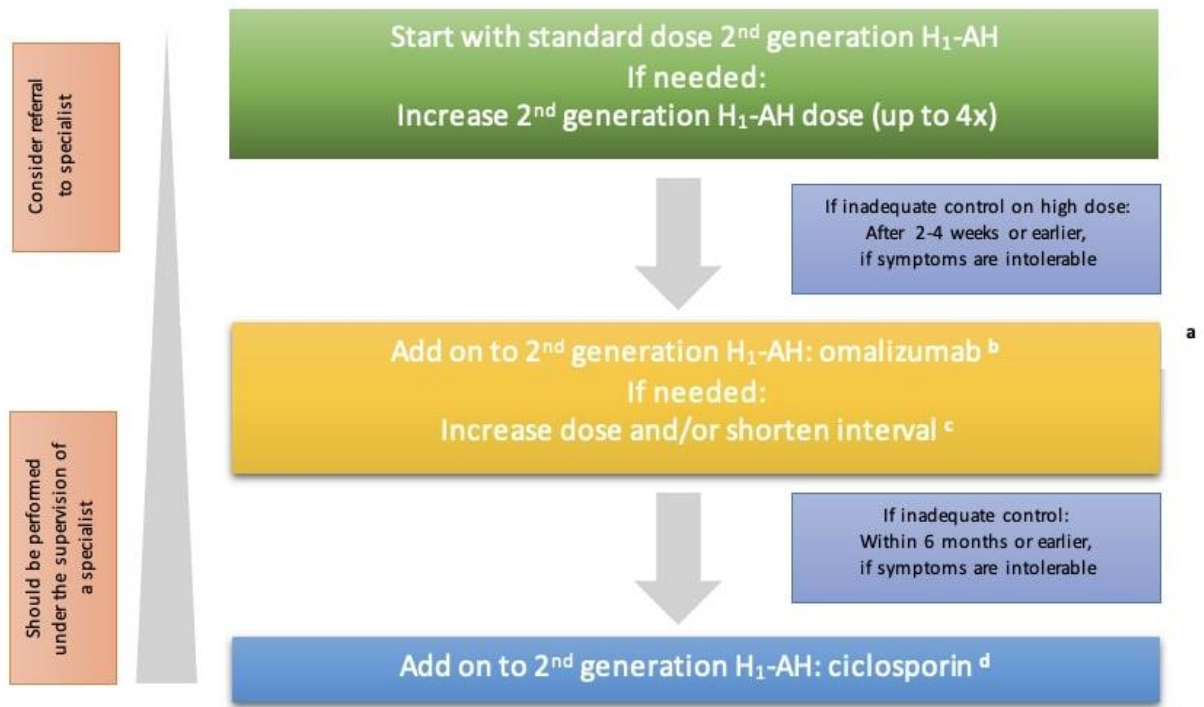
- idiopathic/spontaneous urticaria despite standard combination therapy. *J Allergy Clin Immunol*. 2013;132(1):101-9.
16. Saini SS, Bindslev-Jensen C, Maurer M, et al. Similar efficacy with omalizumab in chronic idiopathic/spontaneous urticaria who remain symptomatic on H1 antihistamine: a randomized, placebo controlled study. *J Invest Dermatol*. 2015;135(1):67-75.
 17. Zhao ZT, Ji CM, Yu WJ, et al. Omalizumab for the treatment of chronic spontaneous urticaria: a meta-analysis of randomized clinical trials. *J Allergy Clin Immunol*. 2016;137(6):1742-50e4.
 18. Casale TB, Bernstein JA, Maurer M, et al. Similar efficacy with omalizumab in chronic idiopathic/spontaneous urticaria despite different background therapy. *J Allergy Clin Immunol Pract*. 2015;3(5):743-50.
 19. Mallipeddi R, Grattan CE. Lack of response of severe steroid dependent chronic urticaria to rituximab. *Clin Exp Dermatol*. 2007;32(3):333-4.
 20. Arkwright PD. Anti-CD20 or anti-IgE therapy for severe chronic autoimmune urticaria. *J Allergy Clin Immunol*. 2009;123(2):510-1.
 21. Chakravarty SD, Yee AF, Paget SA. Rituximab successfully treats refractory chronic autoimmune urticaria caused by IgE receptor autoantibodies. *J Allergy Clin Immunol*. 2011;128(6):1354-5.
 22. Hermes B, Prochazka AK, Haas N, Jurgovsky K, Sticherling M, Henz BM. Upregulation of TNF-alpha and IL-3 expression in lesional and uninvolved skin in different types of urticaria. *J Allergy Clin Immunol*. 1999;103(2):307-14.
 23. Piconi S, Trabattoni D, Lemoli E, et al. Immune profiles of patients with chronic idiopathic urticaria. *Int Arch Allergy Immunol*. 2002;128(1):59-66.
 24. Magerl M, Philipp S, Manasterski M, Friedrich M, Maurer M. Successful treatment of delayed pressure urticaria with anti-TNF-alpha. *J Allergy Clin Immunol*. 2007;119(3):752-4.
 25. Wilson LH, Eliason MJ, Leuferman KM, Hull CM, Powell DL. Treatment of refractory chronic urticaria with tumor necrosis factor-alfa inhibitors. *J Am Acad Dermatol*. 2011;64(6):1221-2.
 26. Kulthanan K, Chaweekulrat P, Komoltri C, et al. Cyclosporine for Chronic Spontaneous Urticaria: A Meta-Analysis and Systematic Review. *J Allergy Clin Immunol Pract*. 2018; 6:586.
 27. Grattan CE, O'Donnell BF, Francis DM, et al. Randomized double-blind study of cyclosporin in chronic 'idiopathic' urticaria. *Br J Dermatol*. 2000; 143:365.
 28. Gach JE, Sabroe RA, Greaves MW, Black AK. Methotrexate-responsive chronic idiopathic urticaria: A report of two cases. *Br J Dermatol*. 2001;145:340-3.
 29. Sagi L, Solomon M, Baum S, Lyakhovitsky A, Trau H, Barzilai A, et al. Evidence for methotrexate as a useful treatment for steroid-dependent chronic urticaria. *Acta Derm Venereol*. 2011;91:303-6.

30. Stack PS. Methotrexate for urticarial vasculitis. *Ann Allergy*. 1994;72:36-8.
31. Sharma VK, Singh S, Ramam M, Kumawat M, Kumar R. A randomized placebo-controlled double-blind pilot study of methotrexate in the treatment of H1 antihistamine-resistant chronic spontaneous urticaria. *Indian J Dermatol Venereol Leprol*. 2014;80:122-8.
32. Shahar E, Bergman R, Guttman-Yassky E, Pollack S. Treatment of severe chronic idiopathic urticaria with oral mycophenolate mofetil in patients not responding to antihistamines and/or corticosteroids. *Int J Dermatol*. 2006;45:1224-7.
33. Zimmerman AB, Berger EM, Elmariah SB, Soter NA. The use of mycophenolate mofetil for the treatment of autoimmune and chronic idiopathic urticaria: Experience in 19 patients. *J Am Acad Dermatol*. 2012;66:767-70.
34. Chaptini C, Sidhu S. Mycophenolate mofetil as a treatment for urticarial dermatitis. *Australas J Dermatol*. 2014;55:275-8.
35. Raghavendran RR, Humphreys F, Kaur MR. Successful use of mycophenolate mofetil to treat severe chronic urticaria in a patient intolerant to ciclosporin. *Clin Exp Dermatol*. 2014;39:68-9.
36. de Silva, Damayanthi H, Rajapakse AC, Rodrigo C, Rajapakse S. Leukotriene receptor antagonists for chronic urticaria: a systematic review. *Iran J Allergy Asthm*. 2014;10:1-6.
37. Bozeman PM, Learn DB, Thomas EL. Inhibition of the human leukocyte enzymes myeloperoxidase and eosinophil peroxidase by dapsone. *Biochem Pharmacol*. 1992; 44:553.
38. Booth SA, Moody CE, Dahl MV, et al. Dapsone suppresses integrin-mediated neutrophil adherence function. *J Invest Dermatol*. 1992;98:135.
39. Theron A, Anderson R. Investigation of the protective effects of the antioxidants ascorbate, cysteine, and dapsone on the phagocyte-mediated oxidative inactivation of human alpha-1-protease inhibitor in vitro. *Am Rev Respir Dis*. 1985; 132:1049.
40. Morgan M, Cooke A, Rogers L, Adams-Huet B, Khan DA. Double-blind placebo-controlled trial of dapsone in antihistamine refractory chronic idiopathic urticaria. *J Allergy Clin Immunol Pract* 2014;2:601-6.
41. Engin B, Ozdemir M. Prospective randomized non-blinded clinical trial on the use of dapsone plus antihistamine vs. Antihistamine in patients with chronic idiopathic urticaria. *J Eur Acad Dermatol Venereol*. 2008;22:481-6.
42. Nürnberg W, Grabbe J, Czarnetzki BM. Urticarial vasculitis syndrome effectively treated with dapsone and pentoxifylline. *Acta Derm Venereol*. 1995;75:54-6.
43. Fortson JS, Zone JJ, Hammond ME, Groggel GC. Hypocomplementemic urticarial vasculitis syndrome responsive to dapsone. *J Am Acad Dermatol*. 1986;15:1137- 42.

44. González P, Soriano V, Caballero T, Niveiro E. Idiopathic angioedema treated with dapson. *Allergol Immunopathol (Madr)*. 2005;33:54-6.
45. Godse K, De A, Zawar V, Shah B, Girdhar M, Rajagopalan M, Krupashankar D S. Consensus statement for the diagnosis and treatment of urticaria: A 2017 update. *Indian J Dermatol*. 2018;63:2-15.
46. Orden RA, Timble H, Saini SS. Efficacy and safety of sulfasalazine in patients with chronic idiopathic urticaria. *Ann Allergy Asthma Immunol* 2014; 112:64.
47. McGirt LY, Vasagar K, Gober LM, et al. Successful treatment of recalcitrant chronic idiopathic urticaria with sulfasalazine. *Arch Dermatol* 2006; 142:1337.
48. Hong JY, Kim MH, Lee JH, Han HS, Seo SJ, Park KY, et al. Phototherapy may be a Useful Adjuvant Therapy for Retractable Chronic Spontaneous Urticaria: A Systematic Review. *Photochem Photobiol*. 2020; 1-10.
49. Khafagy NH, Salem SA, Ghaly EG. Comparative study of systemic psoralen and ultraviolet A and narrowband ultraviolet B in treatment of chronic urticaria. *Photodermatol Photoimmunol Photomed*. 2013; 29:12.
50. Engin B, Ozdemir M, Balevi A, Mevlitoğlu I. Treatment of chronic urticaria with narrowband ultraviolet B phototherapy: a randomized controlled trial. *Acta Derm Venereol*. 2008; 88:247.
51. Horio T. Indications and action mechanisms of phototherapy. *J Dermatol Sci*. 2000; 23 Suppl 1:S17.
52. Bishnoi A, Parsad D, Vinay K, Kumaran MS. Phototherapy using narrowband ultraviolet B and psoralen plus ultraviolet A is beneficial in steroid-dependent antihistamine-refractory chronic urticaria: a randomized, prospective observer-blinded comparative study. *Br J Dermatol*. 2017; 176:62.
53. Sheikh G, Latif I, Lone KS, Hassan I, Jabeen Y, Keen A. Role of adjuvant narrow band ultraviolet B phototherapy in the treatment of chronic urticaria. *Indian J Dermatol*. 2019;64:250.
54. Berroeta I, Clark C, Ibbotson SH, Ferguson J, Dawe RS. Narrow-band (TL-01) ultraviolet B phototherapy for chronic urticaria. *Clin Exp Dermatol*. 2004;29:97-9.
55. Engin B, Ozdemir M, Balevi A, Mevlitoğlu I. Treatment of chronic urticaria with narrowband ultraviolet B phototherapy: A randomized controlled trial. *Acta Derm Venereol*. 2008;88:247-51.
56. Hong JY, Kim MH, Lee JH, Han HS, et al. Phototherapy may be a useful adjuvant therapy for retractable chronic spontaneous urticaria: a systematic review. *Photochemistry and Photobiology*. 2020.
57. Godse KV. Autologous serum skin test in chronic idiopathic urticaria. *Indian J Dermatol Venereol Leprol*. 2004;70: 283-4.
58. Hide M, Francis DM, Grattan CE, Hakimi J, Kochan JP, Greaves MW. Autoantibodies against the high affinity IgE receptor as a cause of histamine release in chronic urticaria. *N Engl J Med*. 1993;328:1599-604.

59. S. Nageswaramma, V. Lakshmi Sarojini, B.Bhavani Pujitha, G.Sirisha, G.Suma Bindu. Efficacy of autologous serum therapy in chronic urticaria. *Int J Contemp Med Res.* 2017;4(1):110-112.
60. Kumaravel S, Manjula J, Balamurugan L, Sindhuja SD, Anandan H. Chronic Autoimmune Urticaria and Efficacy of Autologous Serum Therapy. *Int J Sci Stud.* 2017;4(11):163-166.
61. Karn D, Kc S. Clinical Outcome of Autologous Serum Therapy in Chronic Idiopathic Urticaria. *J Nepal Health Res Counc.* 2017;15(35):71-74.
62. Tuchinda P, Kulthanan K, Chularojanamontri L, Arunkajohnsak S, Sriussadaporn S. Relationship between vitamin D and chronic spontaneous urticaria: a systematic review *Clin Transl Allergy.* 2018;8:51.
63. Fedorowicz Z, van Zuuren EJ, Hu N. Histamine H2-receptor antagonists for urticaria. *Cochrane Database Syst Rev.* 2012;14.
64. Paul E, Bödeker RH. Treatment of chronic urticaria with terfenadine and ranitidine. A randomized double-blind study in 45 patients. *Eur J Clin Pharmacol.* 1986;31:277-80.
65. Chang HC, Sung CW, Lin MH. Efficacy of autologous whole blood or serum therapy for chronic spontaneous urticaria: a systematic review and meta-analysis. *J Dermatol Treat.* 2019;30(8): 818-25.

Figure 1. Treatment algorithm of CSU based on EAACI/GA 2LEN/ EDF/WAO in 2022. Available from: Zuberbier T, Abdul Latiff AH, Abuzakouk M, et al. The international EAACI/GA²LEN/EuroGuiDerm/APAAACI guideline for the definition, classification, diagnosis and management of urticaria. *Allergy.* 2022;77:734–766.



- a Second line and third line treatment apply only for CU
- b 300mg every 4 weeks
- c Up to 600mg every 2 weeks
- d Up to 5mg/kg body weight

Figure is based on expert consensus and achieved ≥70% agreement in the consensus conference

Journal

Table 1. Level of evidence (LoE) Oxford Centre for Evidence-Based Medicine 2011 for therapy study.

Level I	Level II	Level III	Level IV	Level V
Systematic review of randomized trials or n-of-1 trials	Randomized trial or observational study with dramatic effect	Non-randomized controlled cohort / follow-up study	Case-series, case control studies, or historically controlled studies	Mechanism-based reasoning

Table 2. Adjuvant therapy modality in the chronic urticaria treatment.

Modality	Type	Indication	Dosage	Onset Improvement	LoE
Biologic agent	Omalizumab	CSU/CindU	150 – 300 mg/4 week, sc	1 – 2 week	I
	Rituximab	CSU	375 mg/m ² /week, iv	1 week	IV
	Inhibitor TNF- α (etanercept)	CSU/CindU	50 mg/week, sc	1 week	IV
Immunosuppressant	Cyclosporin	CSU/CindU	3 – 5mg/kgBB/day, po	5 – 7 day	I
	Methotrexate	CSU/CindU	7,5 – 15 mg/week, po	3 week – months	II
	MMF	CSU	1000 – 2000 mg/day, po	12 – 14 week	II
LTRA	Montelukast	CSU/CindU	10 mg/day, po	2 – 4 week	I
H2 Antihistamine	Ranitidine	CSU	150 – 300 mg/day, po	1 – 2 week	I
	Sulfone	Dapsone	CSU/CindU	50 – 100 mg/day, po	1 – 6 week
Sulfasalazine		CSU/CindU	500 – 2000 mg/day, po	3 – 6 months	IV
Phototherapy	NBUVB	CSU/CindU	200 mj/cm ² , 3x/week, naik 10-20%	7 – 8 week	I

Autohemotherapy	AST	CSU	0,05 ml/kgBB/week, im	4 – 7 week	I
Vitamin D	Vitamin D3	CSU	2000 IU/day or 60.000 IU/week, po	4 – 12 week	I

Journal Pre-proof