

Metadichol® and Healthy Skin: One Approach many Possible Cures

PR Raghavan*

Nanorx Inc, P.O Box, 131, Chappaqua, New York, 10514, USA

Abstract

Metadichol® is a nano formulation of long-chain lipid alcohols derived from food. It is an inverse agonist of Vitamin D receptor (VDR), Aryl hydrocarbon receptor (AHR), and ROR gamma (RORC) that could have beneficial effects on skin diseases. We now present case studies of patients with various skin diseases who have symptoms mitigated on treatment with Metadichol. The proposed mechanism is that Metadichol by its actions on the above mentioned nuclear receptors affects Th1, Th2, Th17, IL17 and IL22 and IL23 pathways that exacerbate many skin diseases.

Metadichol is the first molecule to successfully navigate around the problems involved with promiscuous ligands and targets. It fulfills the goals of the emerging field of Polypharmacology i.e. a single drug is able to bind to multiple targets beyond the "one drug, one target" concept. We show how Metadichol is an innovative treatment for treating multiple skin diseases like eczema, acne, diabetic wounds, viral and bacterial infection and also improving skin texture. Metadichol® is a safe, non-toxic, low-cost solution and is an alternative to numerous clinical candidates in combating over 3000 skin diseases.

Keywords: Metadichol; Psoriasis; Eczema; Acne; Warts; Diabetic wounds; VDR; Vitamin D; Calcitriol; Inverse agonist; TH1; TH2; ROR gamma T; (RORγt); Interleukin (IL)-17; IL-23; Tumor necrosis factor (TNFα); IL-17-producing T (T17) cells; T helper (Th)1 cells; Th22 cells

Introduction

The skin is the largest organ of the body that protects against mechanical and chemical threats, it provides innate and adaptive immune defenses, enables thermo-regulation and vitamin D production, and acts as the sensory organ of touch (1). Skin is frequently damaged because it is directly in the 'firing line' and is a significant cause of global disease burden, affecting millions of people worldwide. There are more than 3000 known diseases of the skin (2). Aging, environmental and genetic factors, and trauma can result in the development of a diverse set of skin diseases (3,4).

A cosmetically disfiguring disorder can have a significant impact and can cause considerable discomfort and disability. Most of the chronic skin diseases like Atopic Eczema, Psoriasis, Vitiligo and leg ulcers, are not immediately life-threatening but are an enormous burden on health status and quality of life issues, physical as well as mental. One in four Americans (85 million) were seen by a physician for skin disease in 2013. In 2013, skin disease resulted in direct health care costs of \$75 billion and indirect lost opportunity costs of \$11 billion. Another study estimated the cost of Psoriasis alone in the US to be \$112 billion [5].

Skin diseases become more prevalent as population ages worldwide [6], which directly affects the overall health (Figure 1). A wellness and prevention approach to protecting the skin can substantially reduce the incidence of non-melanoma and other skin cancers [7]. Maintaining a healthier skin enables better health outcomes leading to a more active and engaged life.

There are many Biologic agents used today to treat different cutaneous diseases. Antibiotics like Tetracycline, Rifampicin, Retinoids like Acitretin, Anti-androgens like Metformin and Spironolactone and immunosuppression drugs like Cyclosporine. Some mAbs are in use for psoriasis, atopic dermatitis, melanoma, and other skin diseases target IL-17 and TNF alpha [8,9]. Many promising target therapies are

Some common skin diseases			
Acne	Contact dermatitis	Nonmelanoma skin cancer	Viral HSV/HZV
Actinic damage	Cutaneous infections	Pruritus	Fungal diseases
Atopic dermatitis/eczema	Cutaneous lymphoma	Psoriasis	Vitiligo
Noncancerous skin growths benign, scars/cysts	Drug eruptions	Rosacea	Wounds and burns
Bullous diseases	Hair and nail disorders	Seborrheic dermatitis	Rosacea
Melanoma	HPV / warts	Ulcers	Seborrheic dermatitis

Figure 1: Representation of International Classification of Diseases, Ninth Revision (ICD-9) diagnosis codes.

under study, including bio-similars that reduce costs associated with these originator monoclonal antibodies. Despite progress in clinical dermatology, a more thorough pathophysiology of diverse skin conditions is needed to target 3000 skin diseases with a cheaper and cost-effective solution (Figure 1).

Metadichol [10] is a nano lipid formulation of long-chain naturally occurring alcohols. It is an inverse agonist of VDR (Vitamin D receptor), AHR (Aryl hydrocarbon receptor), RORC (Retinoic acid receptor gamma) and a TNF alpha inhibitor. We have recently documented how Metadichol is effective against Psoriasis [11]. The gene cluster targeted by Metadichol are predicted by Topp gene cluster program [12] to target other skin diseases as shown in Figure 2. One can also see that skin diseases are related to each other as predicted by Disease Connect [13], which is based on curated experimental data as shown in Figure 3.

*Corresponding author: PR Raghavan, Nanorx Inc, P.O. box 131, Chappaqua, New York, 10514, USA, Tel: +19146710224; E-mail: raghavan@nanorxinc.com

Received January 22, 2018; Accepted February 26, 2018; Published March 12, 2018

Citation: Raghavan PR (2018) Metadichol® and Healthy Skin: One Approach many Possible Cures. J Clin Exp Dermatol Res 9: 445. doi:10.4172/2155-9554.1000445

Copyright: © 2018 Raghavan PR. This is an open-access article distributed under the terms of the Creative Commons Attribution License, which permits unrestricted use, distribution, and reproduction in any medium, provided the original author and source are credited.

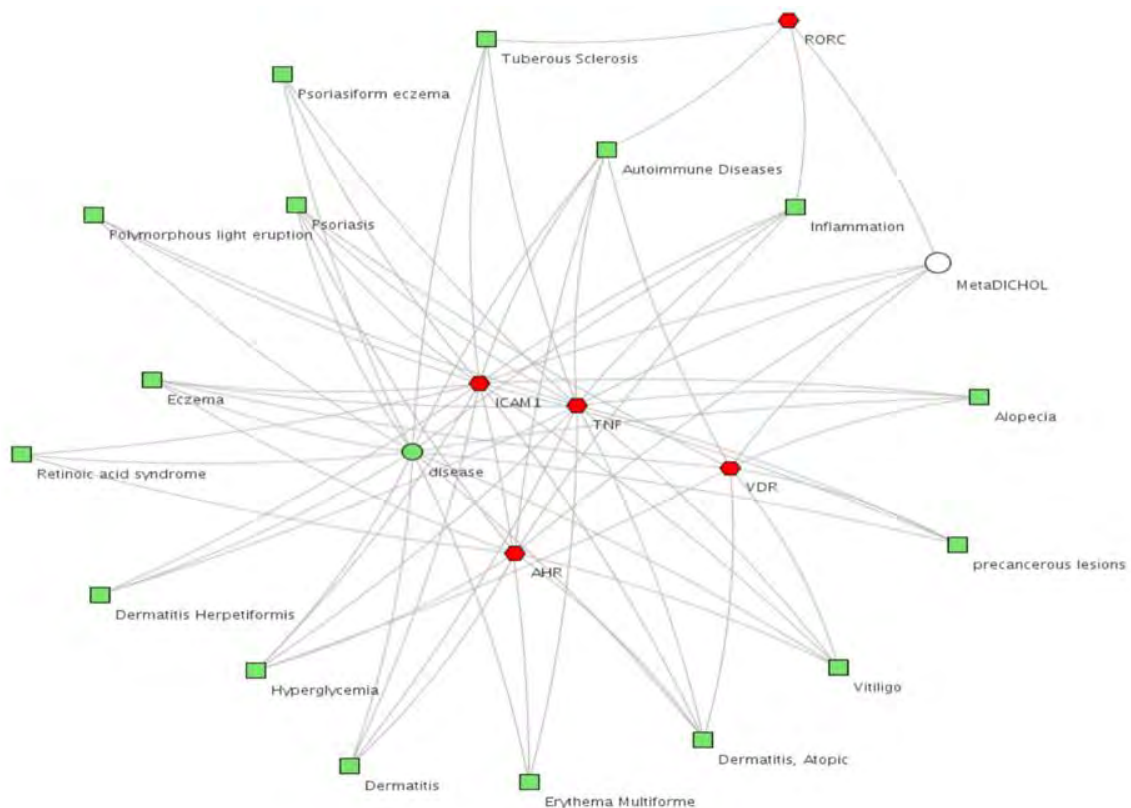


Figure 2: The gene cluster targeted by Metadichol by Topp gene cluster program to target other skin diseases.

with a p-value less 10^{-9} . Given this high degree of correlation predicted. We decided to test this hypothesis below by treating Metadichol on patients with various skin diseases.

Case Studies

Presented are case studies related to skin diseases. Metadichol (5 mg/ml) is sprayed on the affected area and or taken orally. In some cases, Metadichol gel is used the concentration was 2.5 mg/gm and applied to affected areas (Figures 4-38).

Results and Discussion

The results confirm the theoretical prediction as show in Figures 2 and 3. The clinical case studies presented suggest that there is a common pathway through which Metadichol acts to mitigate the condition be it eczema or viral skin disease like herpes or diabetic wound healing and skin rejuvenation. Metadichol binds to Vitamin D receptor (VDR) as an inverse agonist and seems to mimic the well-known actions of 1,25 dihydroxy Vitamin D3 (Vitamin D3) the natural agonist of VDR. The effect of Vitamin D3 are mediated by its binding to the vitamin D receptor (VDR). Once it binds its ligand, VDR dimerizes with a RXR (retinoid X receptor). These VDR-RXR hetero-dimers bind to vitamin D response elements present on target genes [14-16].

In addition to transcriptional activation, the hetero-dimers can displace the nuclear factors of activated T cells resulting in repression of cytokine-related genes [17].

Vitamin D3 suppresses Th-1 cell proliferation leading to the

lowered production of interferon gamma and interleukin-2 [18-20]. Lower levels of circulating cytokines leads to less antigen presentation by dendritic cells, in addition to less T lymphocyte recruitment and proliferation. Expression of Th-2 associated cytokines, including interleukin-4 are increased by Vitamin D3. Overall, vitamin D3 polarizes the adaptive immune system away from Th-1 and toward Th-2 responses. Also, Vitamin D3 suppresses IL-17 production via direct transcription and suppression of IL-17 gene expression [21].

The majority of studies done so far indicate an inverse relationship between the severity of atopic dermatitis, eczema and vitamin D levels. Individuals with AD and eczema treated with vitamin D led to decreased severity of the disease [22,23].

Acne vulgaris is a skin disorder affecting millions of people worldwide. Inflammation resulting from the immune response targeting *Propionibacterium acnes* (*P. acnes*) has a significant role in acne pathogenesis. It has been demonstrated that *P. acnes* are a potent inducer of Th17 and that 1,25OH₂D inhibits *P. acnes*-induced Th17 differentiation, and thereby could be considered as a useful tool in modulating acne [24].

Herpes and shingles are caused by herpes family of viruses, which are generally dormant but they can reactivate under certain conditions. Herpes simplex virus-1 (HSV-1) and herpes simplex virus-2 (HSV-2) can cause oral and genital herpes. Varicella-zoster virus results in chickenpox in children and shingles later in life. The anti-viral effects of vitamin D could be explained by it inducing cathelicidin (in the form of LL-37) and also human

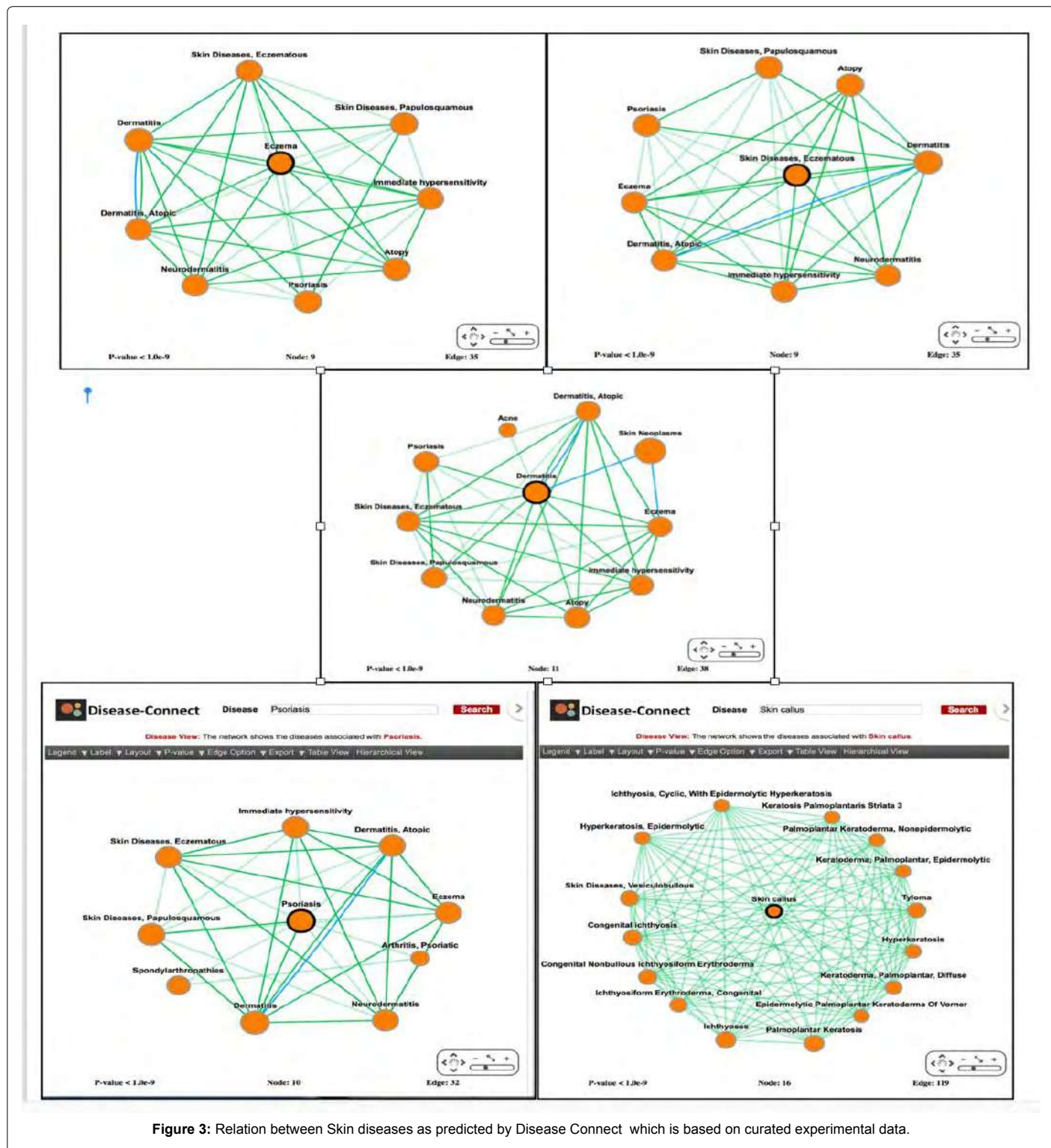


Figure 3: Relation between Skin diseases as predicted by Disease Connect which is based on curated experimental data.

beta-defensin 2, and the likely release of reactive oxygen species [25].

Vitamin D has an essential role in innate immune response modulation. The toll-like receptors (TLRs) in macrophages, polymorphonuclear cells, monocytes, and epithelial cells are central to the innate immune response [26,27]. TLRs recognize pathogen-

associated molecular patterns associated with infectious agents. TLR2 recognizes the lipopolysaccharides of bacteria and also the viral proteins and nucleic acids. Upon recognition, activated TLRs release cytokines that induce expression of antimicrobial peptides and reactive oxygen species. Metadichol has been shown to be active against MRSA bacterial infection [28].

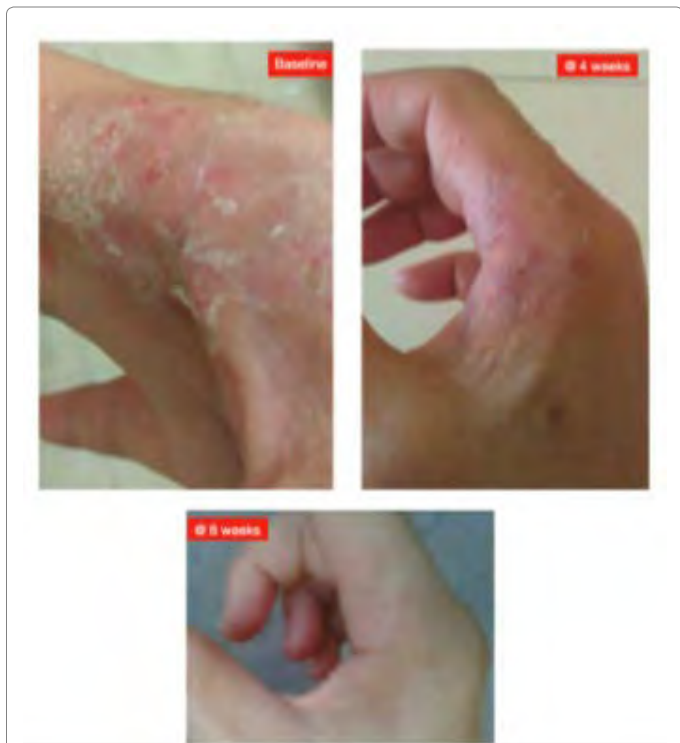

Figure 4: Female-45 with eczema on her right hand for more than ten years. She had tried many medicines and topical drugs but with no success. Treated with Metadichol Nano-Spray in the mouth and on hand for 8 weeks. Her hand eczema healed completely.

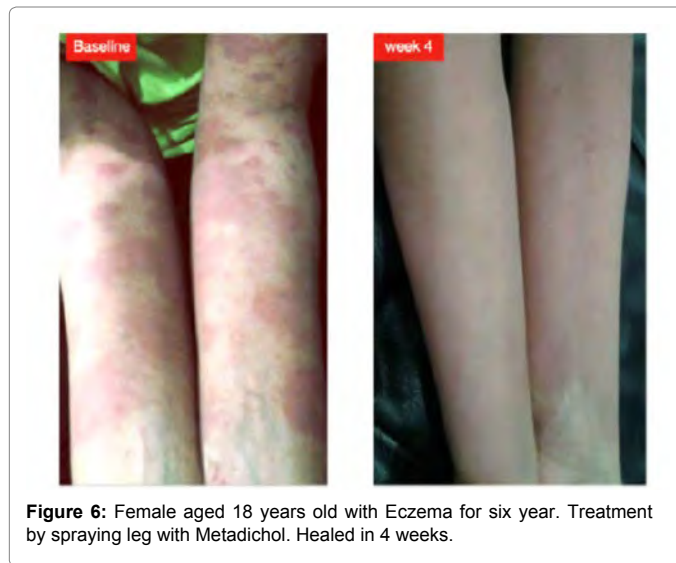

Figure 6: Female aged 18 years old with Eczema for six year. Treatment by spraying leg with Metadichol. Healed in 4 weeks.

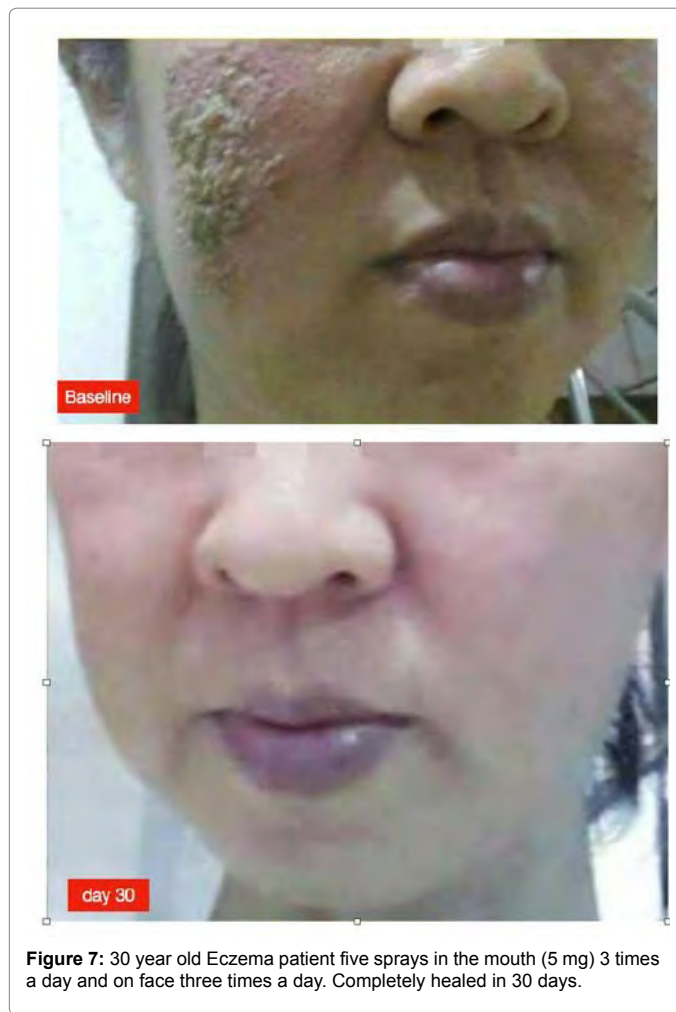


Figure 7: 30 year old Eczema patient five sprays in the mouth (5 mg) 3 times a day and on face three times a day. Completely healed in 30 days.

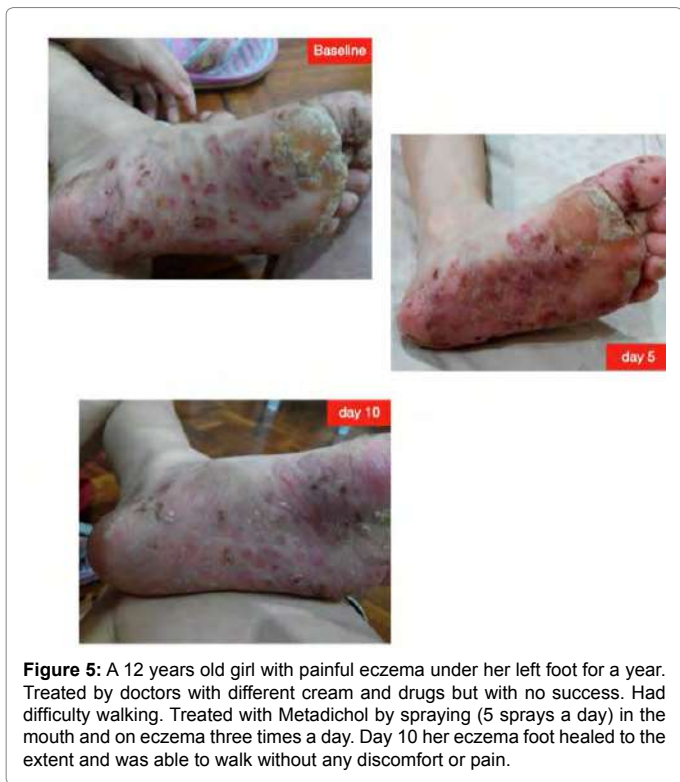

Figure 5: A 12 years old girl with painful eczema under her left foot for a year. Treated by doctors with different cream and drugs but with no success. Had difficulty walking. Treated with Metadichol by spraying (5 sprays a day) in the mouth and on eczema three times a day. Day 10 her eczema foot healed to the extent and was able to walk without any discomfort or pain.

Skin wounds require vitamin D3 to protect against infections to initiate the normal repair process. Vitamin D has an indirect role in wound healing due to its effect on improved glycemic control in 12 weeks among patients with diabetic foot injury and reduced inflammatory markers like ESR, hs-CRP [29]. Vitamin D deficiency

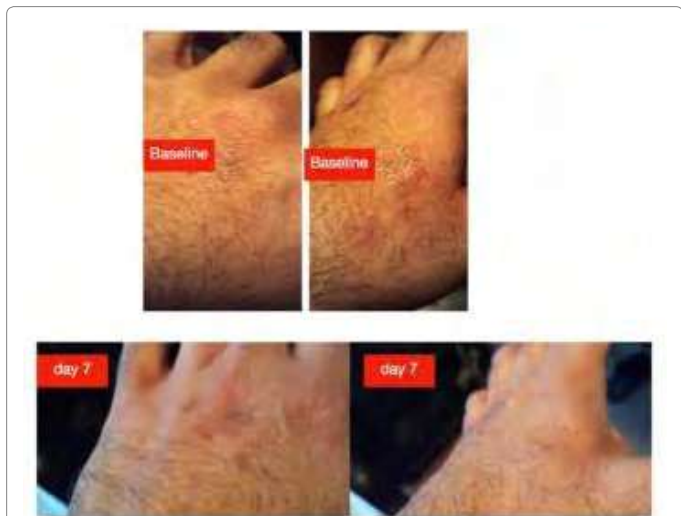

Figure 8: Male 40 Eczema of hand Applied gel on affected areas twice a day.

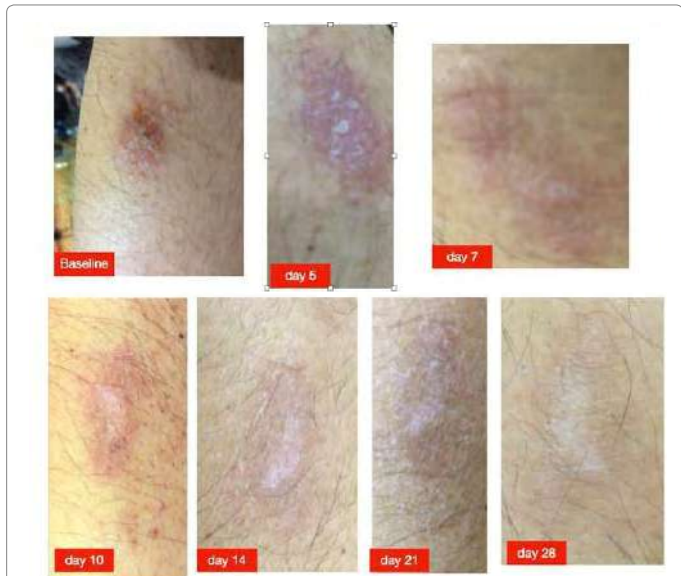


Figure 9: Male 40 Eczema of hand. Sprayed Metadichol on the affected area. Conditions cleared in 7 days.

compromises the body's innate immune system, making a patient more vulnerable to microbes and infections [30]. Vitamin D3 role in innate immunity is to enable keratinocytes to recognize and respond to bacteria and to protect wounds against infection [31] Metadichol as we documented earlier has a powerful effect on diabetic patients [32,33]. Metadichol is an agonist of GPR 120 [34]. This is another pathway through which it can act as shown by Arantes El et al. [35] that the topical use of GPR 120 agonists like polyunsaturated fatty acids (PUFAs) can accelerate skin wound healing. Da Younz et al. [36] have shown that GPR120 agonist treatment of high-fat diet-fed obese mice causes improved glucose tolerance, decreased hyperinsulinemia, increased insulin sensitivity and decreased hepatic steatosis. For wound healing, a decrease in glucose levels leads to improved outcomes.

Atopic Dermatitis (AD) is a common chronic inflammatory skin disease where VDR signaling is essential to be important not only in

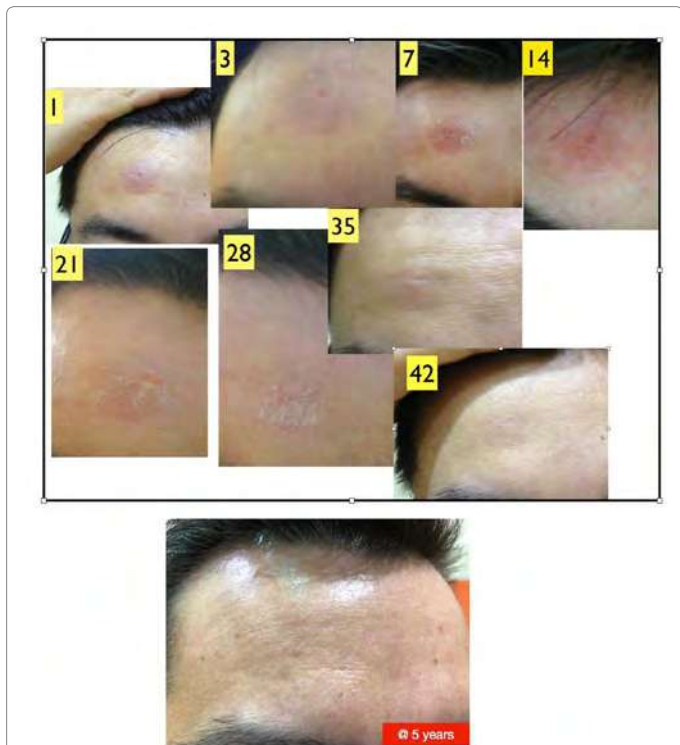


Figure 10: Male 36 years old with eczema. Progress with Metadichol gel day 1 to 42. Gel treatment stopped. After five years no recurrence.

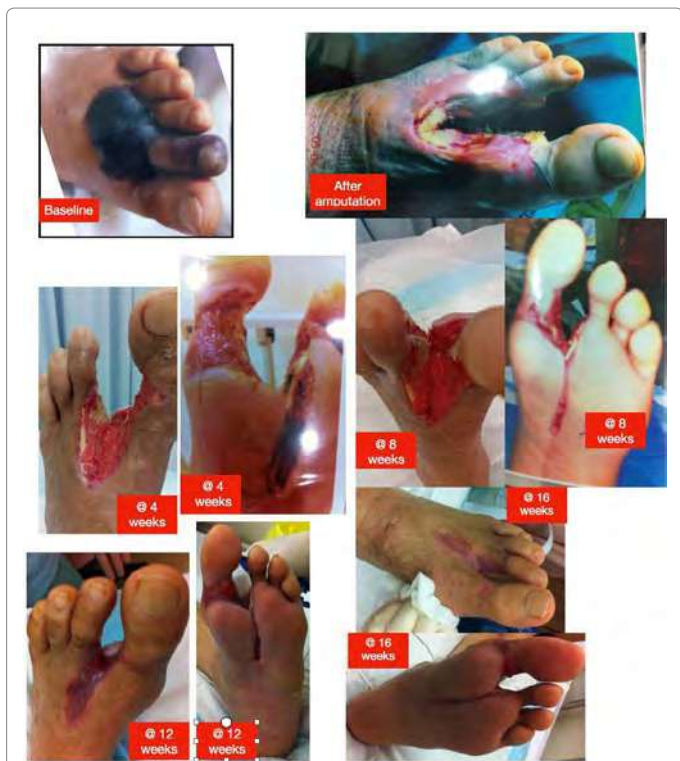

Figure 11: M-50. Type 2 diabetic for ten years. Left index toe was amputated. Sprayed Metadichol on affected area 3 times a day and 5 mg per day orally.

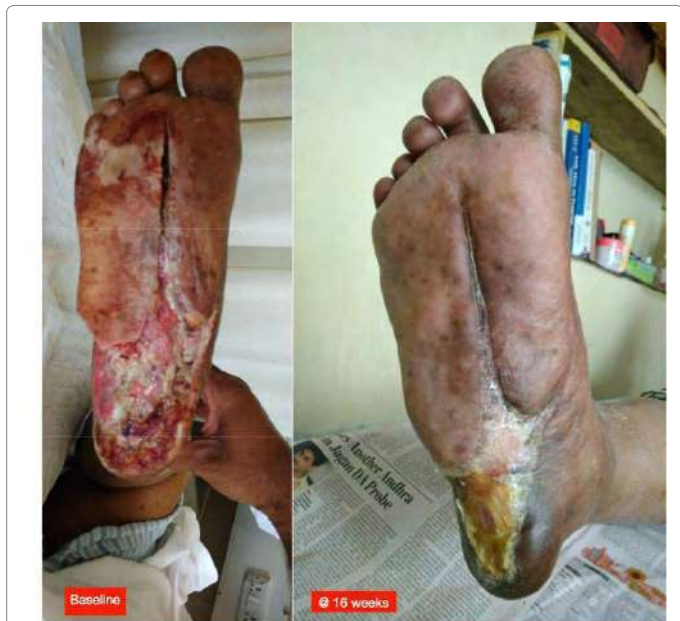

Figure 12: Female 61. The diabetic wound on feet did not heal over two years could not walk. Metadichol sprayed on wound three times a day. Now walks slowly with the heel raised without pain.

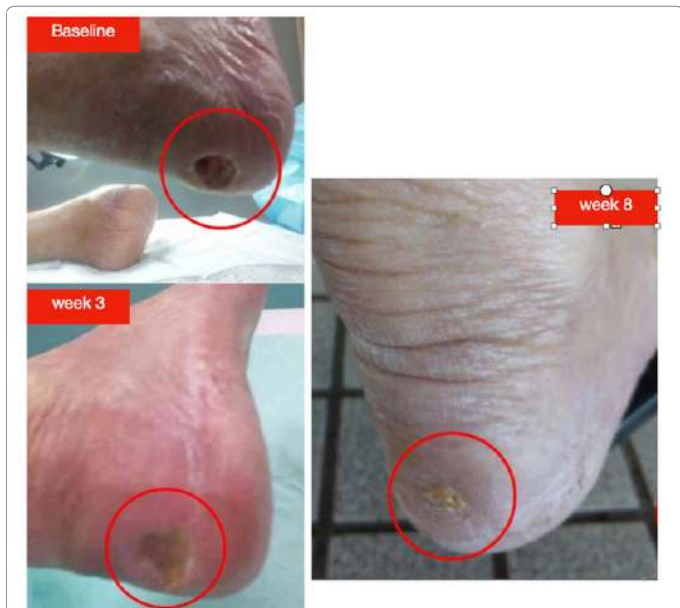

Figure 13: Female 83 diabetics for 25 years. Left foot was amputated at age 76. Right foot has a diabetic wound that did not heal. Sprayed Metadichol on affected area for two months. The diabetic wound on right foot healed.

the immune system but also in particular keratinocytes to regulate skin homeostasis and epidermal barrier function. Hartmann et al. [37] showed that regulatory T cells have a role in the AD, are increased in the skin of VDR agonist-treated mice and induction of skin barrier gene and antimicrobial peptide gene expression in skin lesions of the treated

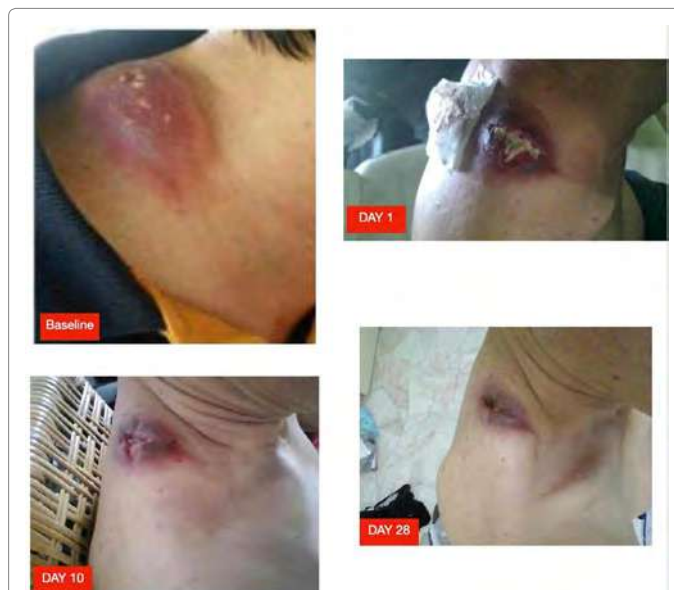


Figure 14: Middle-aged man with a painful tumor on his neck for over 20 years. His tumor could not be operated as he is a Diabetic Metadichol 5 mg per day orally and sprayed on wound. After using Metadichol, the tumor pain was gone within 30 minutes. Yellow pus and blood discharged after a day during the first two weeks. After using Metadichol for one month, the wound is almost healed.

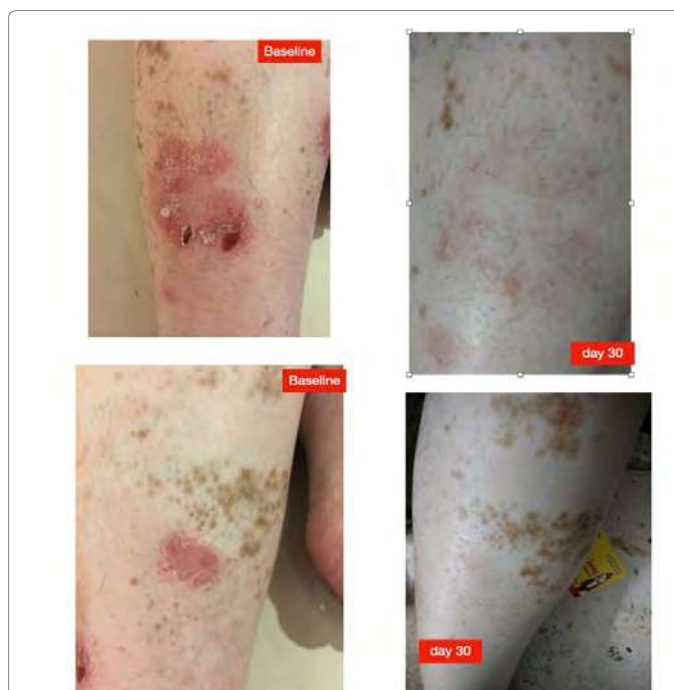

Figure 15: Diabetic Wound-Calf. Subject: Female-52. Had wound for more than six months. It started as a small spot and was prescribed Calapure by a physician. The patient stated the wound always bleed after a hot bath. When scratched, it begins to look very "angry" and red. Metadichol topically and orally twice a day.

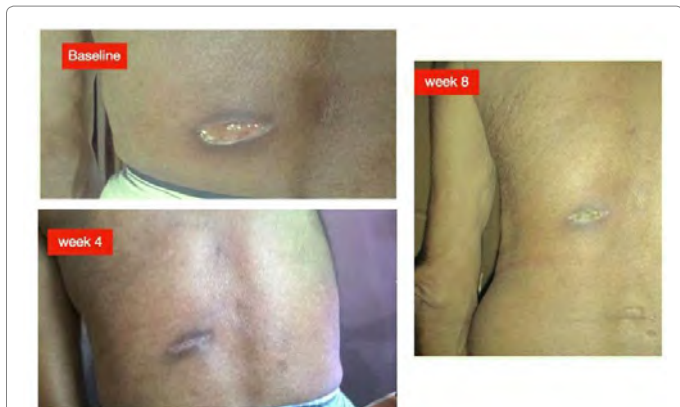


Figure 16: Patient M-65. Carbuncle is a cluster of boils, which drains pus onto the skin. It is usually caused by bacterial infection, most commonly with *Staphylococcus aureus* or *Streptococcus pyogenes*, which can turn lethal. Diagnosed and treated with antibiotics for one year without improvement. Metadichol @ 5 mg per day sprayed on the wound.

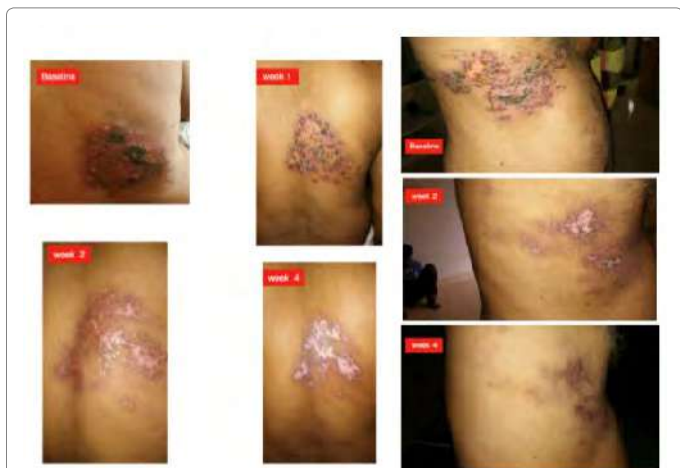


Figure 17: Male-45 Herpes on his back and stomach. Sprayed with metadichol.

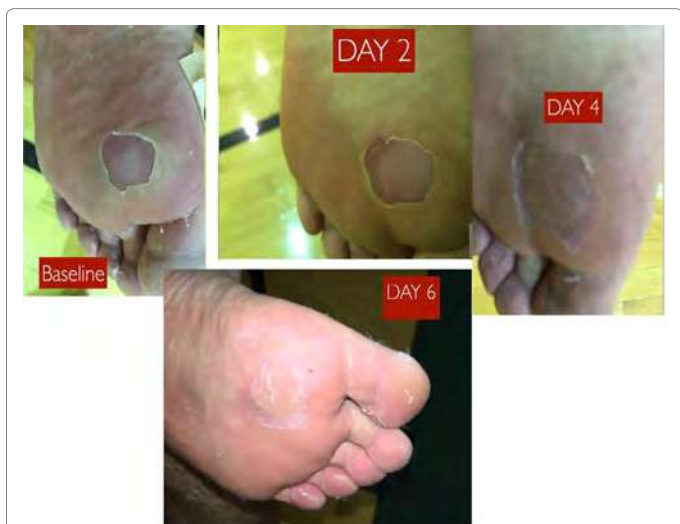

Figure 18: Male 34 fungal infection and skin peeling painful while walking. Applied Metadichol gel on affected are. Pain eased after day 1.

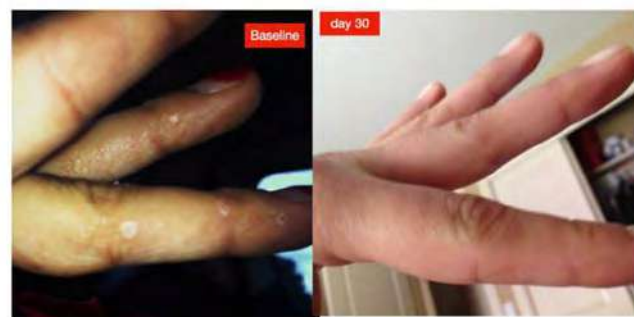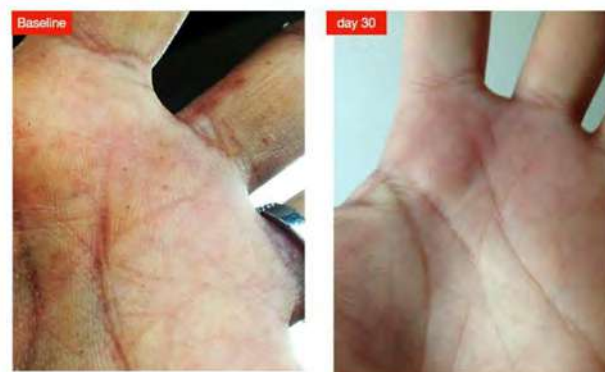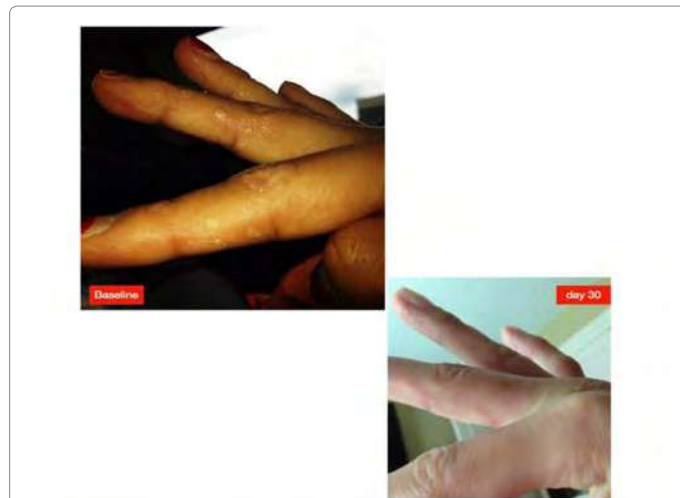


Figure 19: Female, 33 years old. Warts on the palm of hands and fingers. She experienced a sudden outbreak of warts on her hands due to an immune response to toxins in the body. Over 50, dry and rough spots were developing into warts on all fingers: Tiny, brown specks appeared all over palms and fingers, forming into wart heads. Small, circular-shaped spots were scaly and dry. These spots were the beginning of wart heads forming: She noted it looked like small coffee grinds all over palms: Treated by spraying Metadichol on each hand, two times per day. Orally, two sprays (2 mg) per day.

mice. Targeting the VDR with low-calcemic agonists could be a new feasible approach for the AD.

Alopecia results when the immune system attacks the hair follicles, resulting in patterned hair loss. Cianferotti et al. found that vitamin D receptors in the hair follicles play a role in normal hair cycling loss [38]. Mutation of the VDR, in humans and mice, results in alopecia. The actions of VDR that prevent alopecia are ligand-independent.

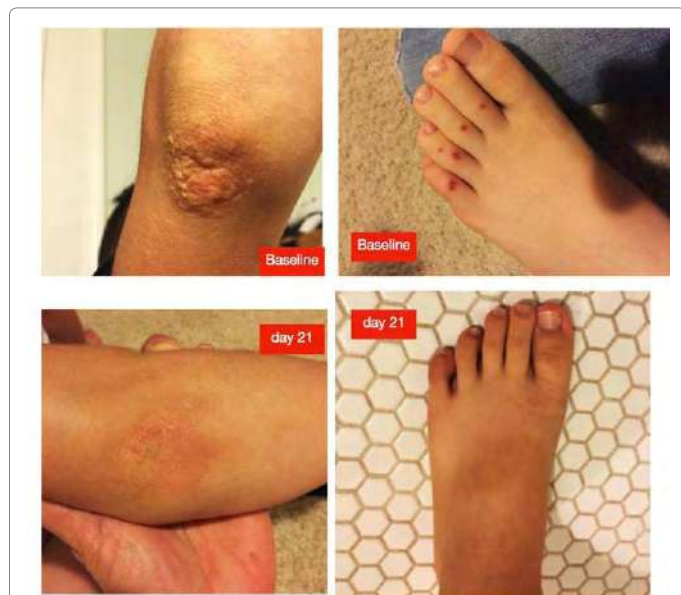

Figure 20: Male, ten years old. Condition: Keratosis Pilaris, Eczema and toe injury scrape from swimming pool. Topically, spray twice a day on the affected area. Rash and inflammation deceased. Scabs faded to healthy skin.

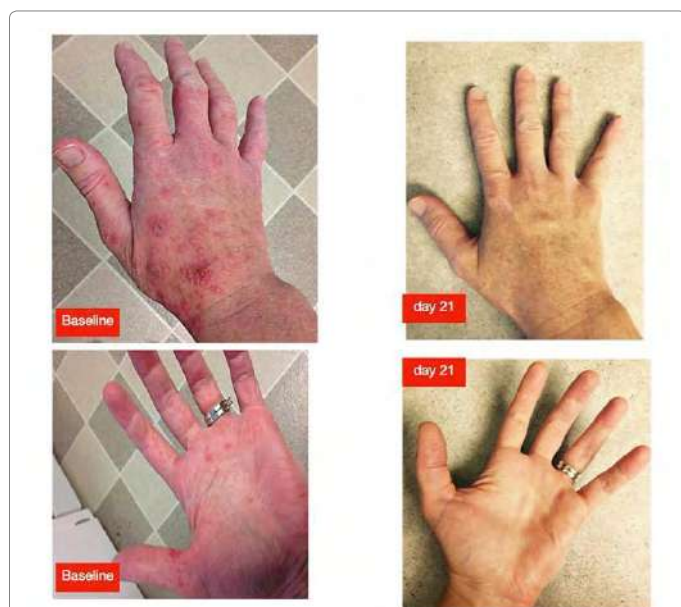

Figure 21: Hand Foot Mouth Virus (HMF). Female, 35 years old contracted HMF virus mostly on hand from her son (see figure 22). She developed red itchy sores on her hands. She was severely allergic to Benadryl. Metadichol Topically and orally 4 times per day.

Mutations in the VDR that disrupt the ability of the unliganded VDR to suppress gene transcription are hypothesized to lead to disruption if the hair cycle that ultimately leads to alopecia [39]. It like hair follicle cycling is dependent on unliganded actions of the VDR [40].

Vitamin C is an antioxidant useful for preventing and treating skin aging. It stimulates the barrier function of the endothelial cells and is proven to have photo protective effects [41,42]. What hampers its uses widely is the inability to delivery into the dermis for collagen production [43].

Metadichol over comes this delivery problem as it increases

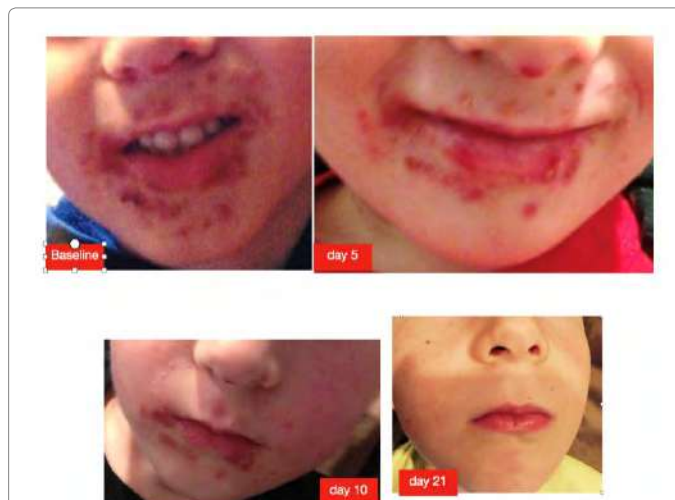


Figure 22: Hand Foot Mouth Virus . Male five years old. Pus oozed from the sores. It was itchy and painful to the point of crying. Metadichol was used topically on affected areas and orally up 5 sprays (5mg) 4 times per day. After one day of using Metadichol sores began to scab and dry out. Less itching on 5th-day, sores drying out and shrinking in size, less redness. Metadichol helped reduce the pain, relieved itching, eased the oozing sores, and stopped the spread of the lesions.

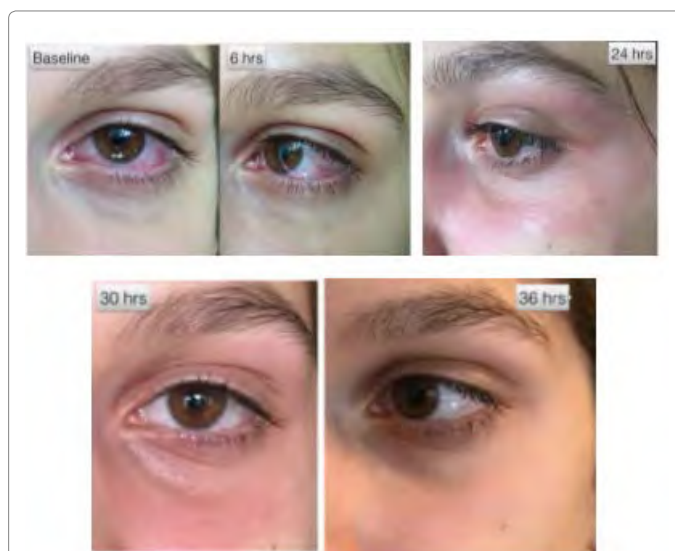


Figure 23: F-14 years old conjunctivitis sprayed Metadichol into eye at 24 h the area around eye turned red and at 36 h completely cleared her eyes.

Vitamin C levels [44,45] over and beyond what is achieved by oral supplementation. Vitamin C is present at cutaneous level, displaying antioxidant, anti-inflammatory, photoprotective properties, and is a known bio stimulator of collagen synthesis [46]. It has a role in the maintenance of dermal collagen, preventing the inactivation of enzymes involved in the biosynthesis of collagen, hydroxylase, and lysine [47].

Vitamin D3 has an essential role in mitigating many skin diseases be it production of AMP's, Th 17 inhibition and directing immune response towards a Th2 outcome [48]. Metadichol binds to VDR as an inverse agonist and based on the result mimics the action of Vitamin D3. Also, its effects are enhanced by its inverse agonist actions on RORC that is involved in the Th17 expression.

Metadichol is an inverse agonist of AHR which is involved

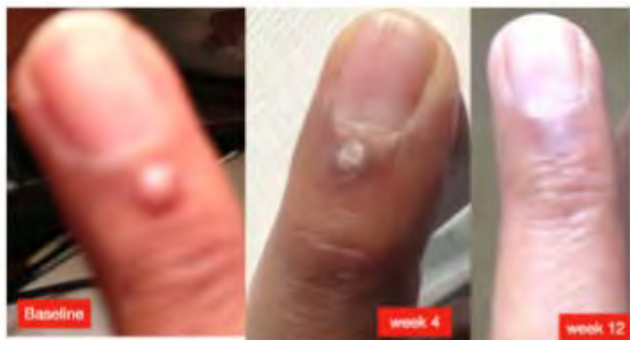

Figure 24: Patient M-58 ganglion cyst that he could not rid with surgery every year for two years and it reappeared in days after each operation. Applied Metadichol gel and it healed in 12 weeks. Five years since last application of gel and no reappearance of Cysts.

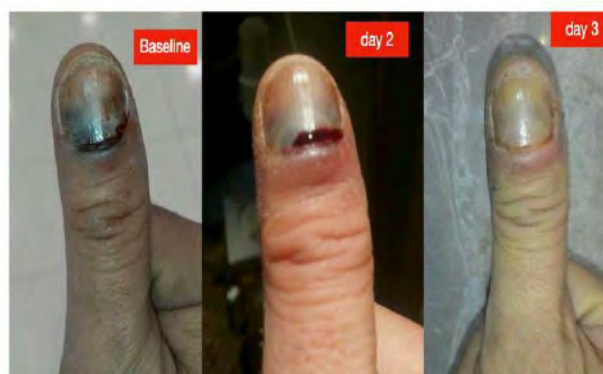


Figure 27: M-25. Thumb Injury caused by a car door. Sprayed with Metadichol complete healing on day 3.

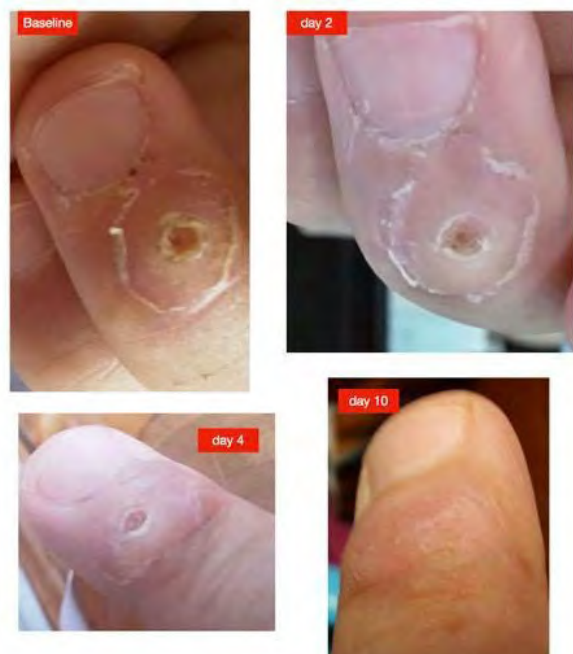

Figure 25: M-35. Finger wound that did not heal. sprayed with Metadichol twice a day.

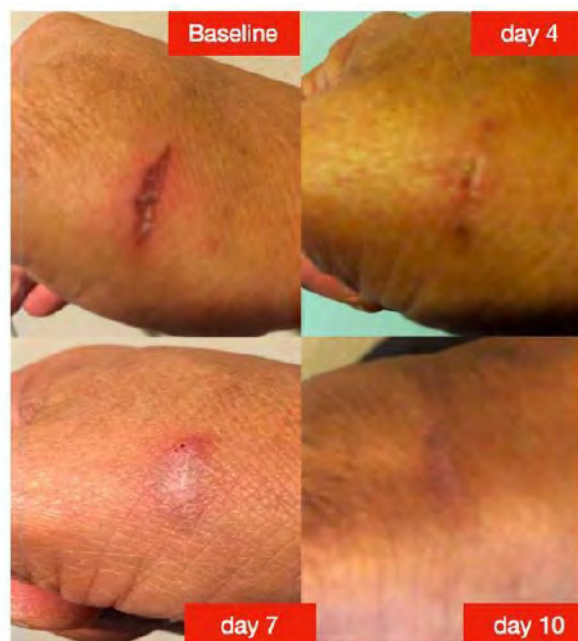

Figure 28: M-65, while cooking spilled hot oil on his hand. Treated with Metadichol sprayed twice a day on affected areas.

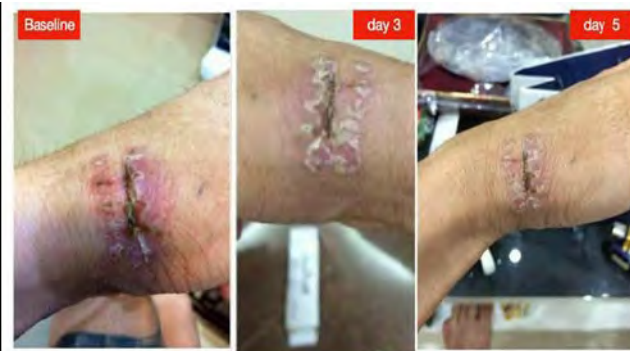

Figure 26: M-30. Deep Laceration on the arm and Metadichol sprayed on affected areas twice a day.

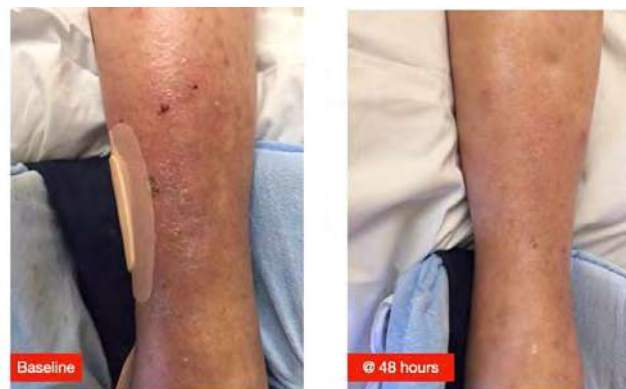

Figure 29: Male 85 bed sore infection in Hospital. Gel applications on the affected area. Complete healing on 3rd day.

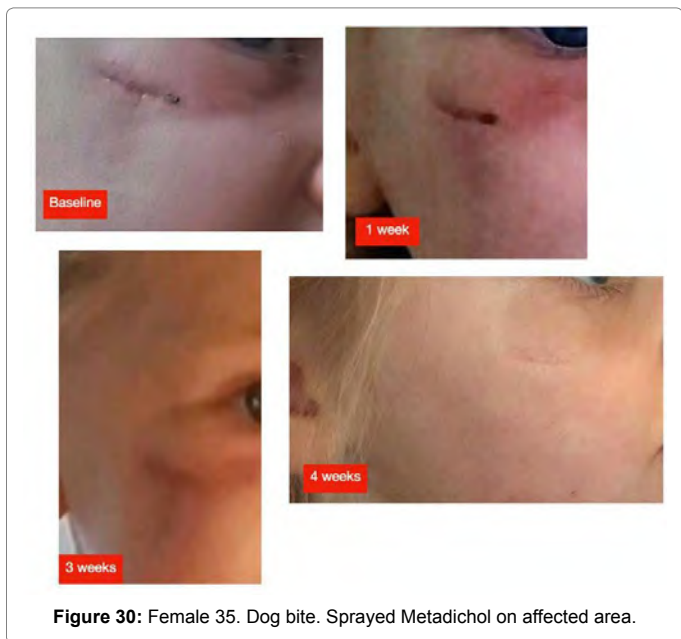

Figure 30: Female 35. Dog bite. Sprayed Metadichol on affected area.

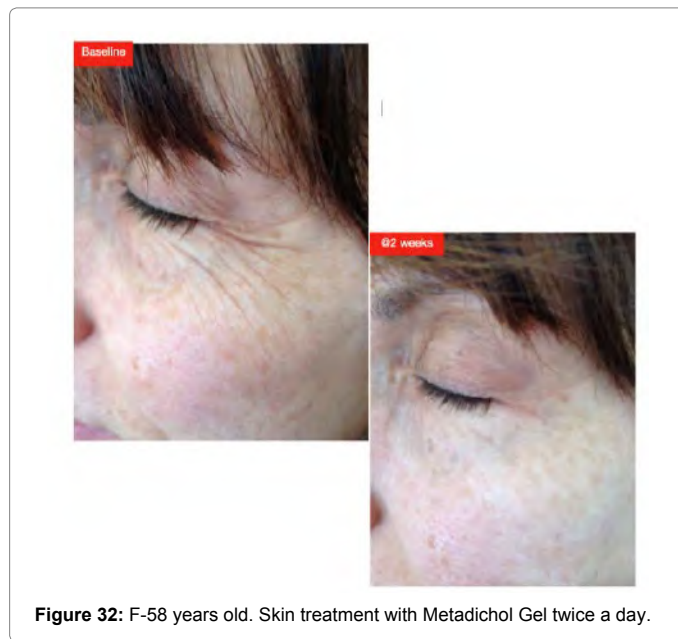

Figure 32: F-58 years old. Skin treatment with Metadichol Gel twice a day.

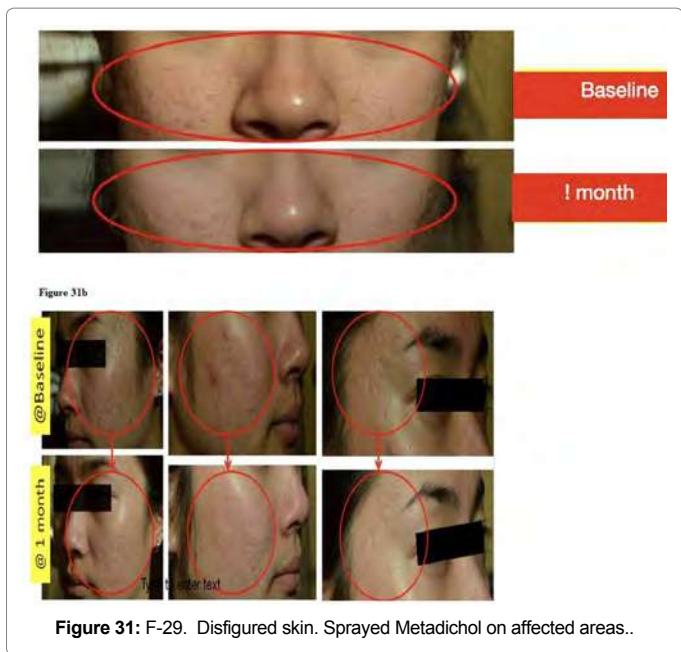

Figure 31: F-29. Disfigured skin. Sprayed Metadichol on affected areas..

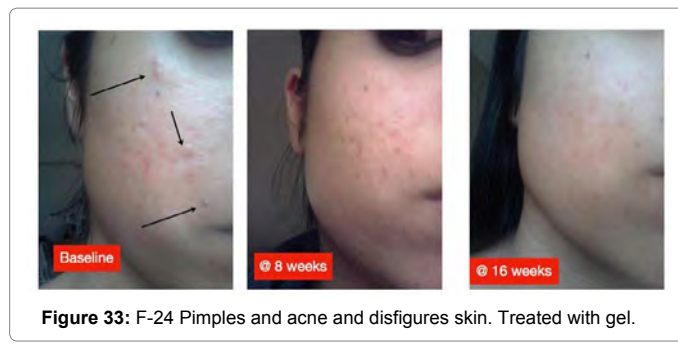

Figure 33: F-24 Pimples and acne and disfigures skin. Treated with gel.

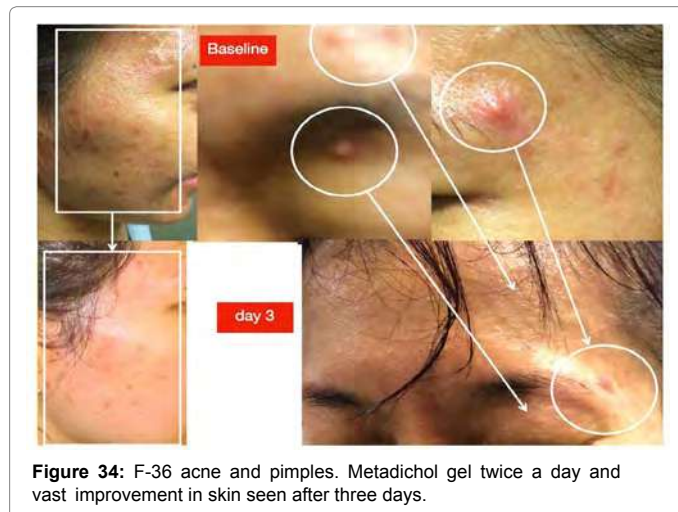


Figure 34: F-36 acne and pimples. Metadichol gel twice a day and vast improvement in skin seen after three days.

in adaptive responses against UVB or topical chemicals and plays a role in maintaining homeostasis of skin cells and skin immunity. AHR ligands have applications in the prevention and treatment of skin disease [49].

Metadichol is an inhibitor of TNF alpha a significant cytokine of inflammatory diseases of the skin. The anti-TNF alpha arsenal is currently dominated by Etanercept, a fusion protein composed of a soluble TNF alpha receptor, and infliximab, a chimeric monoclonal antibody. Many dermatological diseases will probably benefit from these new treatments. These are expensive, with unknown long-term side effects. A small number of Studies have already demonstrated their effects in cutaneous and articular psoriasis. Encouraging sporadic results suggest other potential indications of Behcet's disease, bullous dermatitis, neutrophilic dermatitis, toxic

epidermal necrolysis, and systemic vasculitis [50].

Metadichol is also an inhibitor of ICAM 1 and expression of cell-adhesion molecules are known to contribute to inadequate inflammatory response seen in inflammatory skin diseases. The epidermis of patients with inflammatory skin diseases exhibits increased expression of ICAM 1 [51].

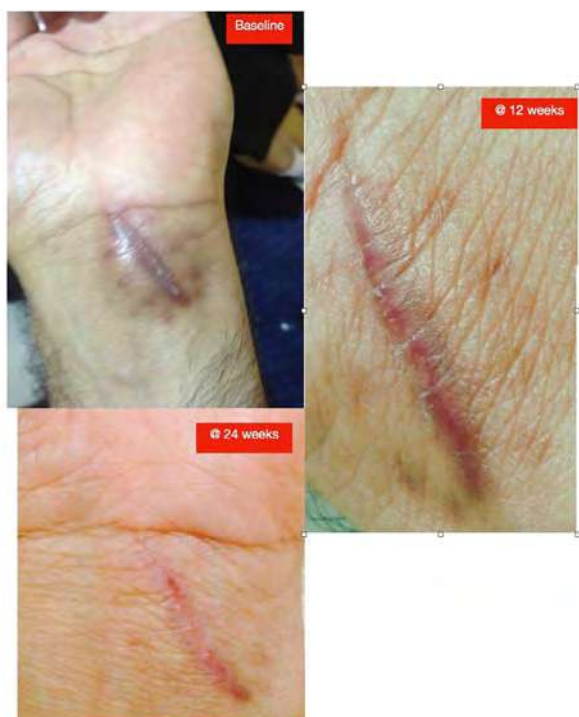

Figure 35: Male 35. Knife wound that needed 20 stitches. Scar did not disappear after one year. Applied Gel and most of the ugly scar disappeared and with new skin formation.

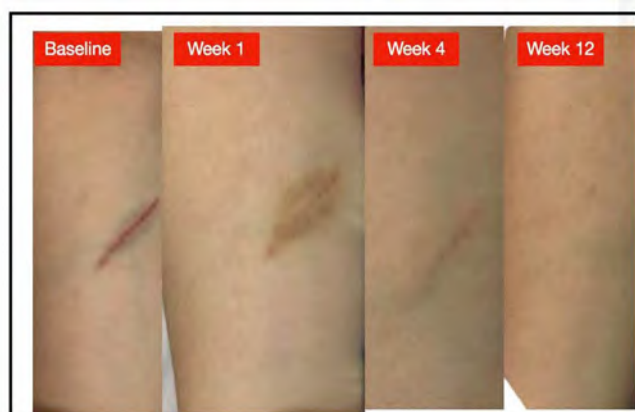

Figure 36: M-25 with a wound on arm. Metadichol gel applied on affected area led to elimination of skin marks.

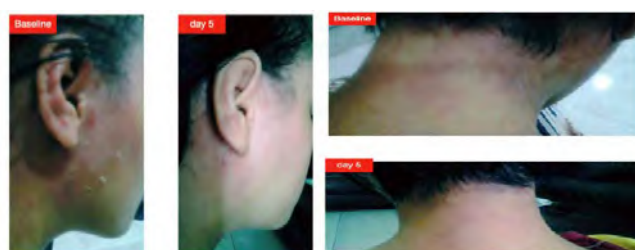

Figure 37: Female 17 with eczema since she was a baby. Treated with Metadichol orally and on skin. 4 days later, her eczema spots showed vast improvement

Conclusion

Given that there are approximately 50000 diseases [52] that confront humanity. The dogma 'one drug' 'one target' 'one disease' is not a viable option. A Poly pharmacological approach [53-55], i.e., single drug acting on multiple targets of a unique disease pathway or a single drug working on multiple targets on multiple disease pathways is an emerging approach that needs to be exploited.

Metadichol is first in this class of molecules. It acts on varied diseases and through multiple pathways. It is also a food-based ingredient devoid of any side effects and could be the harbinger of changes that can impact the healthcare industry. Metadichol by its actions on VDR, AHR, RORC, TNF alpha and ICAM1 efficiently shuts down the many pathways that are involved in the inflammatory process in the pathogenesis of skin diseases. This explains why Metadichol is useful in many types of skin diseases based on the results we have presented. Given that there are over 3000 skin diseases and it would be virtually impossible to treat them one by one, Molecules like Metadichol a safe food-based ingredient will hopefully fulfill the quest to reduce the burden of skin diseases worldwide.

References

1. Chuong CM, Nickoloff BJ, Elias PM, Goldsmith LA, Macher E, et al. (2002) What is the 'true' function of skin? *Exp Dermatol* 11: 159-187.
2. Bickers DR, Lim HW, Margolis D, Weinstock MA, Goodman C, et al. (2006) The burden of skin diseases. A joint project of the American Academy of Dermatology Association and the Society for Investigative Dermatology. *J Am Acad Dermatol* 55: 490-500.
3. Hay RJ, Johns NE, Williams HC, Bolliger IW, Dellavalle RP et al. (2014) The global burden of skin disease in 2010: an analysis of the prevalence and impact of skin conditions. *J Invest Dermatol* 134: 1527-1534.
4. Segre JA (2006) Epidermal barrier formation and recovery in skin disorders. *J Clin Invest*. 16: 1150-1158.
5. Brezinski EA, Dhillon JS, Armstrong AW (2015) Economic Burden of Psoriasis in the United States. A Systematic Review *JAMA Dermatol* 151: 651-658.
6. Pierce J (2000) Guiding Principles For Age-Friendly Businesses 1:22.
7. Kottner J, Lichterfeld A, Blume-Peytavi U (2013) Maintaining skin integrity in the aged: A systematic review. *Br J Dermatol* 169: 528-542.
8. Blauvelt A, Reich K, Tsai TF, Vanaclocha F, Kingo K, et al. (2015) Secukinumab is superior to ustekinumab in clearing skin of subjects with moderate to severe plaque psoriasis: CLEAR, a randomized controlled trial. *J Am Acad Dermatol* 73: 400-409.
9. Zamora-Atenza C, Diaz-Torne C, Geli C, Diaz-Lopez C, Ortiz MA, et al. (2014) Adalimumab regulates intracellular TNF α production in patients with rheumatoid arthritis. *Arthritis Res Ther* 16: R153.
10. Raghavan PR, US Patents: 8,722,093 (2014); 9,034,383 (2015); 9,006,292 (2015).
11. Raghavan PR (2017) Metadichol, A Novel ROR Gamma Inverse Agonist and Its Applications in Psoriasis. *J Clin Exp Dermatol Res* 8: 433.
12. Kaimal V, Bardes EE, Tabar SC, Jegga AG, Aronow BJ (2010) ToppCluster: a multiple gene list feature analyzer for comparative enrichment clustering and network-based dissection of biological systems. *Nucleic Acids Res* 38: W96-102.
13. Liu CC, Tseng YT, Li W, Wu CY, Mayzus I, et al. (2014) DiseaseConnect: a comprehensive web server for mechanism-based disease-disease connections *Nucleic Acids Res* 42: W137-W146.
14. Chawla A, Repa R, Evans M, Mangelsord DJ (2001) Nuclear receptors and lipid physiology: opening the X-files. *Science* 294:1866-1870.
15. Lin R, White JH (2004) The pleiotropic actions of vitamin D. *Bioessays*. 26: 21-28.
16. Yasmin R, Williams RM, Xu M, Noy N, et al. (2005) Nuclear import of the retinoid X receptor, the vitamin D receptor, and their mutual heterodimer. *J Biol Chem* 280: 40152-40160.

17. Takeuchi A, Reddy GS, Kobayashi T, Okano T, Park J, et al. (1998) Nuclear factor of activated T cells (NFAT) as a molecular target for 1,25-dihydroxy vitamin D3-mediated effects. *J Immunol* 160: 209-218.
18. Chen S, Sims GP, Chen XX, Gu YY, Chen S, et al. (2007) Modulatory effects of 1,25-dihydroxy vitamin D3 on human B cell differentiation. *J Immunol* 179: 1634-1647.
19. Lemire JM, Archer DC, Beck L, Spiegelberg HL (1995) Immunosuppressive actions of 1,25-dihydroxy vitamin D3: preferential inhibition of Th1 functions. *J Nutr* 125: 1704S-1708S.
20. Van Etten E, Mathieu C (2005) Immunoregulation by 1,25-dihydroxy vitamin D3: basic concepts. *J Steroid Biochem Mol Biol* 97: 93-101.
21. Joshi S, Pantalena LC, Liu XK, Gaffen SL, Liu H, et al. (2011) 1,25-dihydroxyvitamin D (3) ameliorates Th17 autoimmunity via transcriptional modulation of interleukin-17A. *Mol Cell Biol* 31: 3653-3669.
22. Mutgi K, Koo J (2013) Update on the role of systemic vitamin d in atopic dermatitis. *Pediatr Dermatol* 30: 303-337.
23. Heimbeck I, Wjst M, Apfelbacher CJ (2013) Low vitamin D serum level is inversely associated with eczema in children and adolescents in Germany. *Allergy* 68: 906-910.
24. Agak GW, Qin M, Nobe J, Kim MH, Krutzyk SR, et al. (2014) Propionibacterium acnes induces an IL-17 response in acne vulgaris that is regulated by vitamin A and vitamin D. *J Invest Dermatol* 134: 366-373.
25. Jeremy A, Beard A, Striker A (2011) Vitamin D and the anti-viral state. *J Clin Virol* 50: 194-200.
26. Liu PT, Krutzyk SR, Modlin RL (2013) Therapeutic implications of the TLR and VDR partnership. *Trends Mol Med* 13: 117-124.
27. Medzhitov R (2007) Recognition of the microorganisms and activation of the immune response. *Nature* 15: 819-826.
28. Raghavan PR (2017) Metadichol® and MRSA Infections: A Case Report. *J Infect Dis Ther* 5: 317.
29. Razzaghi R, Pourbagheri H, Momen-Heravi M, Bahmani F, Shadi J, et al. (2017) The effects of vitamin D supplementation on wound healing and metabolic status in patients with diabetic foot ulcer: A randomized, double-blind, placebo-controlled trial. *J Diabetes Complications* 31: 766-772.
30. Schaubert J, Dorschner RA, Coda AB (2011) *Advances in Skin & Wound Care*: November 2011. 24: 498.
31. Robert SJA, Dorschner, Coda AB, Büchau AS, Liu PT, et al. (2007) Injury enhances TLR2 function and antimicrobial peptide expression through a vitamin D dependent mechanism. *J Clin Invest* 117: 803-811.
32. Raghavan PR (2016) Metadichol and Type 2 Diabetes A case report. *J Sci Healing Outcomes* 8: 5-10.
33. Raghavan, PR (2010) Case Report of Type1. Diabetes. *J Sci Healing Outcomes* 2: 24.
34. Raghavan, PR (2017) Metadichol® A Novel Nano Lipid; GPR 120 Agonist. *Int J Diabetes Complications* 1: 1-4.
35. Arantes EL, Dragano N, Ramalho A, Vitorino D, de-Souza GF, et al. 2016. Topical Docosahexaenoic Acid (DHA) Accelerates Skin Wound Healing in Rats and Activates GPR120. *Biol Res Nurs* 18: 411-419.
36. Da Young Oh, Walenta E, Akiyama TE, Lagakos WS, Lackey D, et al. (2014) A Gpr120-selective agonist improves insulin resistance and chronic inflammation in obese mice. *Nat Med* 20: 942-946.
37. Hartmann B, Riedel R, Jörß K, Loddenkemper C (2012) Vitamin D Receptor Activation Improves Allergen-Triggered Eczema in Mice, *Journal of Investigative Dermatology* 132: 330-336.
38. Cianferotti L, Cox M, Skorija K, Demay MB (2007) Vitamin D receptor is essential for normal keratinocyte stem cell function. *Proc Natl Acad Sci USA* 104: 9428-9433.
39. Wang J, Malloy PJ, Feldman D (2007) Interactions of the vitamin D receptor with the co repressor hairless: analysis of hairless mutants in atrichia with papular lesions. *J Biol Chem* 282: 25231-25239.
40. Malloy PJ (2011) The Role of Vitamin D Receptor Mutations in the Development of Alopecia. *Mol Cell Endocrinol* 347: 90-96.
41. Lin JY, Selim MA, Shea CR, Grichnik JM, Omar MM, et al. (2003) UV photoprotection by combination topical antioxidants vitamin C and vitamin E. *J Am Acad Dermatol* 48: 866-874.
42. Barbosa NS, Kalaaji AN (2014) CAM use in dermatology. Is there a potential role for honey, green tea, and vitamin C? *Complement Ther Clin Pract* 20: 11-15.
43. Crisan D, Roman I, Crisan M, Scharffetter-Kochanek K, Badea R (2015) The role of vitamin C in pushing back the boundaries of skin aging: an ultrasonographic approach. *Clin Cosmetol Invest Dermatol* 8: 463-470.
44. Raghavan PR (2017) Metadichol® Induced High Levels of Vitamin C: Case Studies. *Vitam Miner* 6: 169.
45. Raghavan PR (2017) Metadichol® and Vitamin C Increase In Vivo, an Open-Label Study. *Vitam Miner* 6: 163.
46. Boyera N, Galey I, Bernard BA (1998) Effect of vitamin C and its derivatives on collagen synthesis and cross-linking by normal human fibroblasts. *Int J Cosmet Sci* 20: 151-158.
47. Nusgens BV, Humbert P, Rougier A, Colige AC, Haftek M, et al. (2001) Topically applied vitamin C enhances the mRNA level of collagens I and III, their processing enzymes and tissue inhibitor of matrix metalloproteinase 1 in the human dermis. *J Invest Dermatol* 116: 853-859.
48. Aranow C (2011) Vitamin D and the Immune System. *J Investig Med* 59: 881-886.
49. Esser C, Bargon I, Weighardt H, Haarmann-Stemmann T, Krutmann J, et al. (2013) Functions of the aryl hydrocarbon receptor in the skin. *Semin Immunopathol* 35: 677-91.
50. Mahe E, Descamps V (2002) Anti-TNF alpha in dermatology. *Ann Dermatol Venereol* 129: 1374-1379.
51. Bennion SD, Middleton MH, David-Bajar KM, Brice S, Norris DA (1995) In three types of interface dermatitis, different patterns of expression of intercellular adhesion molecule-1 (ICAM-1) indicate different triggers of disease. *J Invest Dermatol* 105: 71S-79S.
52. Noa Rappaport, Twik M, Plaschkes I, Nudel R, Iny Stein T, Leviitt J, et al. (2017) MalaCards: an amalgamated human disease compendium with diverse clinical and genetic annotation and structured search. *Nucleic Acids Res* 45: D877-D887.
53. Yildirim MA, Goh KI, Cusick ME, Barabási AL, Vidal M (2007) Drug-target network. *Nat Biotechnol* 25: 1119-1126.
54. Boran ADW, Iyengar R (2010) Systems approaches to polypharmacology and drug discovery. *Curr Opin Drug Discov Develop* 13: 297-309.
55. Hopkins AL (2007) Network pharmacology. *Nat Biotechnol* 25: 1110-1111.