



HHS Public Access

Author manuscript

Exp Eye Res. Author manuscript; available in PMC 2016 May 01.

Published in final edited form as:

Exp Eye Res. 2015 May ; 134: 101–110. doi:10.1016/j.exer.2015.02.019.

Vitamin D: Implications for Ocular Disease and Therapeutic Potential

Rose Y. Reins and **Alison M. McDermott**

The Ocular Surface Institute, University of Houston College of Optometry, 4901 Calhoun Road, Houston, TX 77204-2020 USA

Rose Y. Reins: rose@reins.org; Alison M. McDermott: AMcdermott@OPTOMETRY.UH.EDU

Abstract

Vitamin D is a multifunctional hormone that is now known to play a significant role in a variety of biological functions in addition to its traditional role in regulating calcium homeostasis. There are a large number of studies demonstrating that adequate vitamin D levels are important in maintaining health and show that vitamin D is able to be utilized at local tissue sites. In the eye, we have increasing evidence of the association between disease and vitamin D. In this narrative review, we summarize recent findings on vitamin D and its relationship to various ocular pathologies and the therapeutic potential for some of these, as well as examine the basic science studies that demonstrate that vitamin D is biologically relevant in the eye.

Keywords

Vitamin D; ocular disease; deficiency; anti-inflammatory; genetic variations

1. Introduction

While first identified for its role in calcium homeostasis, vitamin D is now recognized to have many diverse functions including effects on immune regulation, proliferation, differentiation, apoptosis, and angiogenesis (Plum and DeLuca, 2010; Prietl et al., 2013). Vitamin D directly or indirectly regulates up to 5% of the human genome, or over 900 different genes (Wang et al., 2005). In addition, the vitamin D receptor (VDR) is almost ubiquitously expressed (Bouillon et al., 2008). The enzyme necessary for conversion of vitamin D to its functional metabolite has been identified in a number of cell types, which are able to utilize circulating vitamin D to form the biologically active hormone. Extrarenal activation, expression, and gene influence suggest that vitamin D function is widespread, with pleiotropic effects within the tissue microenvironment where it is activated.

© 2015 Published by Elsevier Ltd.

Corresponding author: Rose Y. Reins, University of Houston College of Optometry, 4901 Calhoun Road, Houston, TX 77204-2020, +1 832 640 7673 (phone), +1 713 743 2053 (fax), rose@reins.org.

Publisher's Disclaimer: This is a PDF file of an unedited manuscript that has been accepted for publication. As a service to our customers we are providing this early version of the manuscript. The manuscript will undergo copyediting, typesetting, and review of the resulting proof before it is published in its final citable form. Please note that during the production process errors may be discovered which could affect the content, and all legal disclaimers that apply to the journal pertain.

Vitamin D is obtained from two sources: dietary consumption (fatty fish, fortified foods, supplementation, for example) and local production in the skin (Figure 1) (Kamen and Tangpricha, 2010; White, 2008). Exposure to ultraviolet B radiation (UVB 290–315nm) generates vitamin D from 7-dehydrocholesterol through a series of thermal and photochemical reactions in the epidermis. Subsequently, vitamin D undergoes two hydroxylation steps to form the active hormone (Kamen and Tangpricha, 2010; Schaubert and Gallo, 2008). In the liver, vitamin D is hydroxylated to 25-hydroxyvitamin D₃ (25D₃), the primary circulating form, by cytochrome p450 enzymes CYP2R1 and CYP27A1 (Bouillon et al., 2008). Further modification to form the fully functional 1,25-dihydroxyvitamin D₃ (1,25D₃) classically occurs in the kidneys, mediated by 1-alpha-hydroxylase, CYP27B1; however, there are an increasing number of extrarenal tissues that are being identified that are also able to activate vitamin D. 24-hydroxylation, catalyzed by CYP24A1, regulates vitamin D metabolite levels through catabolism of both 25D₃ and 1,25D₃, leading to the excretion of the 24-hydroxylated products (Jones et al., 2014; Prosser and Jones, 2004). Active vitamin D binds to its nuclear hormone receptor, the VDR, which heterodimerizes with retinoic X receptor, and binds to both positive and negative vitamin D response elements (VDRE) in target genes. The VDR then recruits co-activators, mediator complex, and chromatin-modifying enzymes to influence gene transcription (Kim et al., 2005).

Vitamin D status is assessed by measuring circulating 25D₃ concentrations, which has a much longer half-life than 1,25D₃ (~ 2 weeks versus ~4 hours) and is present in higher circulating concentrations (Holick et al., 2011). Although the range of values varies slightly, in general, optimal serum 25D₃ levels should be between 30–80 ng/mL (75–200 nmol/L), with deficiency/insufficiency recognized to be 25D <20 ng/mL (50 nmol/L) (Gröber et al., 2013; Holick, 2007; Kennel et al., 2010). The Institute of Medicine, Food and Nutrition Board recommends the adequate intake of vitamin D for most people to be 600IU per day to maintain a healthy status, with an increased intake of 800IU per day for individuals over age 70 (Institute of Medicine (US) Committee to Review Dietary Reference Intakes for Vitamin D and Calcium, 2011).

There is a growing body of research on locally produced vitamin D and its tissue specific effects (Adams and Hewison, 2012). In the eye, vitamin D target cells were first identified by the presence of vitamin D-dependent calcium binding protein, or calbindin, which was shown to be expressed throughout the human retina (Verstappen et al., 1986). Immunohistochemical staining later identified the presence of VDR in the epithelium of the cornea, lens, ciliary body, and retinal pigment epithelium, as well as the corneal endothelium, ganglion cell layer, and retinal photoreceptors in the human eye (Johnson et al., 1995). Recently, the presence of vitamin D hydroxylases (CYP27B1, CYP27A1, CYP2R1, and CYP24A1) has been demonstrated in corneal epithelial, endothelial, scleral fibroblasts, nonpigmented ciliary body epithelial, and adult retinal pigment epithelial cell lines (Alsalem et al., 2014; Yin et al., 2011), suggesting that ocular cells have the machinery to activate and regulate vitamin D metabolism. Indeed, most of these cell types were found to be able to convert 25D₃ into the functionally active 1,25D₃ (Alsalem et al., 2014). Excitingly, corneal limbal epithelial cells were able to produce vitamin D, *de novo*, in

culture when exposed to UVB, similar to cells of the skin (Lin et al., 2012), potentially providing a local source of vitamin D to the ocular surface (Figure 1). Other sources of vitamin D in the eye could be the aqueous and vitreous humor and tear film, in which vitamin D metabolites have been shown to be present in rabbits and increase with oral vitamin D supplementation (Lin et al., 2012; Yin et al., 2011).

With the expression of the receptor and vitamin D regulatory enzymes throughout the eye, studying vitamin D in relation to ocular tissues and pathologies is biologically significant. There is increasing evidence that vitamin D is important in the maintenance of ocular health. This review summarizes epidemiological and basic science studies on vitamin D (Table 1) with a focus on the pathophysiology of various eye diseases and conditions and potential therapeutic roles for this versatile molecule.

2. Vitamin D studies in the eye 2.1. Myopia

Myopia development is multifactorial, with a combination of genetic and environmental factors playing a role in increased axial elongation. Epidemiological studies have shown that time spent outdoors is protective against myopia development (French et al., 2013; Guggenheim et al., 2012; Rose et al., 2008; Sherwin et al., 2012). Therefore, vitamin D status and pathway genetic variations are being examined in relation to myopia to determine if vitamin D plays a role. In a small multiple regression study, subjects with myopia (<-0.75 diopter) had lower serum 25D₃ levels compared to non-myopes after adjustment for dietary intakes. While these results suggested vitamin D status could be related to myopia risk, a larger study was needed to confirm this (Mutti and Marks, 2011).

In 2014, a study was published correlating vitamin D levels and myopia in 2038 Korean subjects (Choi et al., 2014). Vitamin D deficiency is very common in the Korean population, particularly adolescents, and myopia rates are increasing (Choi et al., 2011; Yoon et al., 2011). Testing the hypothesis that vitamin D plays a role in myopia risk, Choi et al. (2014) found that spherical equivalent was positively correlated with serum 25D₃ levels in myopic participants from the Korea National Health and Nutrition Examination Survey (2008–2011), after adjusting for age and sex. This association was particularly significant in the high myopia group. In addition, serum 25D₃ concentration was also significantly associated with myopia after adjusting for confounding factors such as socioeconomic level, rural versus urban residence, daily milk and calcium intakes, and smoking history. Several variables were not taken into account (time spent outdoors and sunlight exposure) which have been shown to affect myopia development and vitamin D levels and therefore could have influenced the results of this study. However, although the association is small, this study, as Mutti commented, was important in providing evidence that vitamin D could be a potential therapeutic option to control the increasing rates of myopia (Mutti, 2014).

Another large study examined the association between vitamin D levels and myopia in participants from the Western Australian Pregnancy Cohort (Raine) Study (Yazar et al., 2014). In this study, the authors analyzed potentially confounding variables, such as age, parental myopia, ethnicity, education, time spent outdoors, and ocular sun exposure,

measured by conjunctival UV autofluorescence (CUVAF) score. Seasonal variability in serum 25D₃ concentrations was also taken into account in the analysis.

With a total of 946 total participants, myopic participants had significantly lower serum 25D₃ levels than nonmyopic subjects. In addition, the likelihood of being myopic decreased with increasing 25D₃ levels in multivariable regression models adjusting for time spent outdoors and CUVAF as well as the fully adjusted model. It is important to note that serum 25D₃ concentrations increased with increasing CUVAF; therefore, as Yazar comments, further studies examining vitamin D levels and sun exposure preceding myopia development would be very helpful in determining vitamin D's importance in protecting against myopia.

Guggenheim et al. performed a large study using prospective data from the Avon Longitudinal Study of Parents and Children (ALSPAC) to determine if the protective effect of time spent outdoors on myopia was mediated by vitamin D (Guggenheim et al., 2014). They found, as others have reported, that time spent outdoors was associated with increased 25D₃ levels and reduced incidence of myopia. Also, vitamin D levels were negatively correlated with myopia. However, the protective effect of time spent outdoors was not attenuated when serum 25D₃ or 25D₂ was added to the model. This study suggests that vitamin D is not the protective factor in time spent outdoors in regards to myopia development. Several important limitations of this study, such as determination of time spent outdoors using a single questionnaire and refractive error without cycloplegia, should be mentioned here. Further studies that address the causality of protection from time outdoors are definitely warranted.

Genetic polymorphisms in vitamin D pathway genes have been associated with an increased risk for various ocular pathologies, as well as vitamin D status (Table 2). Several studies have examined variations in the VDR as potential risk factors for myopia development. The VDR gene is located near loci identified to be associated with myopia (MYP-3) (Annamaneni et al., 2011). In addition, deregulated calcium homeostasis has been implicated in ciliary muscle dysfunction, leading to problems with emmetropization and mechanical stress (Dulhunty et al., 2006). Therefore, in addition to the protective effect of time spent outdoors, vitamin D's ability to regulate calcium levels also suggests that it could be involved in myopia progression. In a multivariate analysis of a Caucasian cohort, a single-nucleotide polymorphism (SNP) in the VDR was found to be significantly associated with the presence of myopia. In a subgroup of myopes from this study (between -0.75 and -4.00 D), three SNPs in the VDR were identified that were significantly linked to myopia (Mutti et al., 2011). The *FokI* VDR polymorphism, however, which has been found to affect calcium homeostasis (Gross et al., 1996; Jurutka et al., 2001), was not found to confer risk for either high or low myopia, although the frequency of the f allele was higher in females, particularly in those subjects with low myopia (Annamaneni et al., 2011).

An interesting topic for expanded exploration is the relationship of vitamin D status to the global and ethnic differences seen in myopia rates. Although vitamin D deficiency is a widespread health issue, low serum levels are more frequent in Asian and Middle Eastern populations (Mithal et al., 2009). Darker skin coloration, higher latitudes, low sun exposure, age, and diet all contribute significantly to deficiency (Kift et al., 2013; Lee et al., 2014;

Mithal et al., 2009). Similarly, myopia development is associated with a range of both environmental and genetic components (Sherwin and Mackey, 2013) and rates are increasing worldwide, particularly in East and Southeast Asian populations (Choi et al., 2011; Yoon et al., 2011). In total, data suggest a link between vitamin D status and myopia; however the biological significance and mechanism of this protection needs to be addressed and further studies are needed to confirm these findings.

2.2. Retinoblastoma

First identified for its ability to regulate calcium absorption, vitamin D is now recognized to have antineoplastic activity against many types of cancers. It has been shown to influence cell differentiation, induce apoptosis, inhibit angiogenesis, and arrest cell growth in various tumors (Frampton et al., 1983; Krishnan et al., 2010; Leyssens et al., 2013; Nagakura et al., 1986; Picotto et al., 2012; Szyszka et al., 2012). In 1966, Verhoeff hypothesized that vitamin D could be an effective treatment for retinoblastoma based on the observation that tumors undergoing spontaneous regression frequently had calcifications (Verhoeff, 1966). Although it has since been shown that vitamin D treatment does not induce tumor calcification (Albert et al., 1992), vitamin D has been proven effective both *in vitro* and in animal models of retinoblastoma in inhibiting tumor cell growth (Sabet et al., 1999).

Early studies showed the presence of the VDR in Y79 cells, a human retinoblastoma cell line, both in culture and in tumors of Y79 cells injected subcutaneously into athymic nude mice, a xenograft model of the disease (Albert et al., 2002; Saulenas et al., 1988; Wagner et al., 2003). Y79 and Weri-RB1 cells also expressed the CYP24A1 gene (Morrison et al., 2011). Human retinoblastoma tissue and tumors from LH beta-Tag transgenic mice, a model in which the overexpression of the SV40 T antigen induces retinal tumors similar to human disease (Suárez et al., 2007; Windle et al., 1990), also expressed the receptor, suggesting that these tumors would be responsive to vitamin D treatment (Albert et al., 2002; Wagner et al., 2003). 1,25D₃ treatment did inhibit Y79 cell growth *in vitro*, inducing G0/G1 cell cycle arrest, and apoptosis, or programmed cell death, of the tumor cells. Mechanistically, 1,25D₃ upregulated Bax, a pro-apoptotic protein, while decreasing the expression of anti-apoptotic Bcl-2, contributing to the increase in cell death (Albert et al., 2002). In both the xenograft and transgenic models of disease, systemic administration of 1,25D₃ for 5 weeks significantly inhibited tumor growth. 1,25D₃ treatment increased apoptosis of cancer cells (Audo et al., 2003) and inhibited angiogenesis within tumors (Shokravi et al., 1995). Unfortunately, however, even low doses of 1,25D₃ (0.05 µg/day) were toxic and resulted in an increase in mortality and hypercalcemia, as measured by serum calcium and renal calcifications (Albert et al., 2002, 1992; Cohen et al., 1988; Sabet et al., 1999).

An active area of vitamin D research has been the development of VDR agonists which have similar protective actions of 1,25D₃ but have lower calcemic effects. In mouse models of retinoblastoma, several vitamin D analogues have shown promise in reducing tumor growth while having less toxic systemic effects compared to 1,25D₃ (Sabet et al., 1999). Specifically, 1,25-dihydroxy-16-ene-23-yne-vitamin D₃ (16,23-D₃) (Albert et al., 2004, 2002; Sabet et al., 1999; Shternfeld et al., 1996; Wilkerson et al., 1998), 1α-hydroxyvitamin D₂ (1α-OH-D₂) (Albert et al., 2004, 2002; Dawson et al., 2003), and 2-methylene-19-nor-

(20S)-1 α -hydroxybismopregnacalciferol (2Mbisp) (Albert et al., 2005) reduce retinoblastoma tumor size without toxicity. 1 α -OH-D₂ has also been shown to inhibit pigmented intraocular tumor growth in a transgenic model mimicking human choroidal melanoma (Albert et al., 2004). Combination therapies are also a possibility in the treatment of retinoblastoma, where a very low concentration of vitamin D could enhance tumor responsiveness to chemotherapy. One such study has shown that 1,25D₃ administered with Cisplatin significantly reduced tumor growth, while no mortality or toxicity to the kidneys was observed (Kulkarni et al., 2009).

2.3. Age-related Macular Degeneration

Because of its protective role during inflammation, oxidative stress, fibrosis, and angiogenesis, vitamin D has been studied in relation to age-related macular degeneration (AMD). While not classically considered an inflammatory disease, it is now recognized that inflammatory events, such as complement activation, immune cell recruitment, and proinflammatory cytokine release, play a role in the development of AMD (Coleman et al., 2008; Nussenblatt et al. 2009; Wang et al., 2011). Therefore, Parekh et al. first hypothesized that vitamin D could be protective against AMD progression (Parekh et al., 2007). In an analysis using 7752 individuals from the third National Health and Nutrition Examination Survey (1988–1994), those subjects in the highest quintile of serum 25D₃ levels had decreased prevalence of early AMD and drusen versus those in the lowest quintile. However, this inverse relationship between vitamin D levels and early AMD was not observed with advanced AMD, possibly accounted for by the much smaller number of subjects with advanced AMD. Examining the association between consumption of foods high in vitamin D and AMD prevalence, this study also found an inverse relationship between milk consumption and early AMD using a food frequency questionnaire, which asked subjects to recall dietary intakes in the month prior to the study (Parekh et al., 2007).

Based on these results, other epidemiological studies have been performed examining the connection between vitamin D levels and AMD. Day et al. (2012) examined the rate of first diagnosis of both neovascular and nonneovascular AMD in Medicare patients based on vitamin D status. Although they did not find a significant association between AMD incidence and vitamin D deficiency, this retrospective study was not able to use patients' laboratory data, and therefore exact 25D₃ concentrations were not used. In a case study evaluating monozygotic twins with varying AMD phenotypes, twins with less severe AMD and smaller drusen area had higher dietary vitamin D consumption (Seddon et al., 2011). Although, as noted by Annweiler, dietary vitamin D intake does not necessarily correspond to vitamin D status (Annweiler et al., 2012). In a separate retrospective study analyzing 1045 individuals with an AMD diagnosis, no association was found between serum 25D₃ levels and disease (Golan et al., 2011). Although this was a large study, several limitations must be pointed out in interpreting the results. AMD was not categorized by severity and clinical data was not available for the analysis; therefore, early and late AMD cases were not separated. In addition, subjects' use of vitamin D supplementation was not known.

In an evaluation of participants in the Carotenoids in Age-Related Eye Disease Study, when separated by age, higher serum 25D₃ concentration was associated with decreased risk of

early AMD in women younger than 75 years old (Millen et al., 2011). This association, however, was decreased when dietary patterns, BMI, and physical activity were accounted for. Also, most participants were Caucasian, postmenopausal women, and therefore, results were specific to a specialized population. A smaller retrospective study in France found that individuals with low vitamin D serum levels (<50 nmol/L) were also more likely to have AMD, but late-stage AMD in particular (Graffe et al., 2012). A large, cross-sectional study of participants in the Korean National Health and Nutrition Examination Survey (2008–2012), also found an inverse association between 25D₃ levels and late AMD, however only in men and not with early AMD after adjustment for age, sun exposure, smoking, and heart disease (Kim et al., 2014).

Following up an earlier study, Graffe et al. used optical coherence tomography to measure pathological changes preceding disease and found that vitamin D insufficiency (< 50 nmol/L) was associated with reduced macular thickness (Graffe et al., 2014). Singh et al. (2013) specifically examined subretinal fibrosis in patients with advanced AMD, classified into the Clinical Age-Related Maculopathy Staging (CARMS) group 5. In their single-center study, they found that patients with subretinal fibrosis had significantly lower serum vitamin D levels and were more likely to be vitamin D-insufficient (<50 nmol/L) than patients without fibrosis. This significance was maintained after adjusting for confounding factors such as age, smoking, diet, sex, exercise, and four SNPs known to influence systemic vitamin D concentrations. Interestingly, there was no difference in serum 25D₃ concentrations between genotypes or between clinical groups 1–5. The authors suggest that this specifically links vitamin D deficiency with subretinal fibrosis. Vitamin D is known to play a role in inhibiting fibrosis in other tissues and low concentrations have been implicated in the pathogenesis of fibrotic diseases, partly through inhibition of transforming growth factor beta (TGF-β) (Artaza and Norris, 2009; Halder et al., 2011; Isik et al., 2012; Petta et al., 2010; Ramirez et al., 2010). Based on these results by Singh et al., studies aimed at determining how vitamin D levels influence tissue changes and fibrosis in AMD would be very interesting. They also warrant an examination of a possible protective role for vitamin D during fibrotic events in other eye diseases as well.

Morrison et al. further explored the relationship between vitamin D and AMD risk (Morrison et al., 2011). They found that in a cohort of 481 sibling pairs, neovascular AMD risk went down with increasing ultraviolet irradiance, as measured by UV index. Although not statistically significant, serum vitamin D levels tended to be higher in unaffected subjects. In a larger scale study, which included three different cohorts for a total of 2,528 subjects and was controlled for known AMD risk factors (smoking, gender, and age), single point variations, SNPs, in the CYP24A1 gene, but not VDR, correlated with an increased risk for all AMD subtypes in a meta-analysis. Polymorphisms in 24A1 were located chromosomally in a region that was known previously to have AMD susceptibility loci (Iyengar et al., 2004; Seddon et al., 2003). This study importantly showed a genetic link between AMD prevalence and vitamin D metabolism.

Several genetic variations have been identified as strong risk factors for AMD. In one of these loci, a single-nucleotide polymorphism in the promoter of the *HTRA1* gene (High-temperature requirement factor A1) has been found to significantly increase the likelihood

of AMD development (Chen et al., 2009; Dewan et al., 2006; Tong et al., 2010; Yang et al., 2006). The orthologous *HTRA1* promoter region in the rhesus monkey contains 9 VDR binding sites and interestingly, one of these sites is removed by the AMD-associated *HTRA1* SNP (Pahl et al., 2013). *In vitro* studies demonstrated that stimulation with vitamin D lowered the activity of the wild type *HTRA1* in ARPE-19 cells. Further studies are needed to identify if vitamin D signaling influences this promoter region and if disease associated variations affect these pathways. Additionally, more studies are needed to firmly establish that vitamin D status is a risk factor for AMD development and to determine if vitamin D supplementation affects the development of AMD.

Several interesting studies have examined inflammatory events and neovascularization in the mouse retina with vitamin D treatment. In a study using aging mice, Lee et al. demonstrated that subcutaneous treatment with vitamin D significantly reduced signs of retinal inflammation (Lee et al., 2012). Treated mice had fewer macrophages in the subretinal space, less complement (C3d) deposition on Bruch's membrane, and a reduction in retinal amyloid beta accumulation. In addition, vitamin D treatment improved visual function, as measured by the electroretinogram a-wave. In a mouse model of oxygen-induced ischemic retinopathy, intraperitoneal vitamin D treatment inhibited retinal neovascularization in a dose-dependent manner (Albert et al., 2007). These mouse models suggest that vitamin D supplementation could be protective against both inflammation and angiogenesis in the retina, providing mechanisms of reduced vitamin D being involved in AMD development.

2.4. Diabetic Retinopathy

Vitamin D's ability to inhibit neovascularization also has led researchers to examine the hormone's involvement in diabetic retinopathy (DR) development. In an epidemiological study, Aksoy et al. (2000) found that serum vitamin D concentrations (25D₃) were inversely related to the severity of retinopathy in diabetic patients, with the lowest concentrations of the hormone measured in patients with proliferative DR (Aksoy et al., 2000). Patients without associated retinopathy had the highest serum vitamin D concentrations. A similar study classified patients into diabetic groups based on disease severity and also found that patients with proliferative DR had the lowest mean 25D₃ levels (21.1 ng/mL) (Payne et al., 2012). In addition, vitamin D deficiency was associated with increased risk of retinopathy in an adolescent population with type 1 diabetes (Kaur et al., 2011), however it was not associated with changes in retinal geometric parameters such as vascular branching angle, length-diameter ratio, or tortuosity (Poon et al., 2013).

Genetic variations in the VDR have also been associated with diabetic retinopathy. In a cohort of Caucasian patients with type 1 diabetes, patients with the *FokI* VDR polymorphism (FF genotype), had a lower incidence of advanced diabetic retinopathy, particularly in those patients whose duration of diabetes was less than 25 years (Taverna et al., 2005). The *FokI* substitution is a functional polymorphism which has been reported to increase immune cell activity (van Etten et al., 2007) and therefore could have a protective effect on DR development. In other studies, the VDR *BsmI* gene polymorphism was also

associated with risk of DR (Bun et al., 2009) and the Taq I polymorphism with severe DR (Taverna et al., 2002).

Looking to an animal model to study vitamin D's ability to protect against retinopathy, Ren et al. used a rat model of type 2 diabetes (Ren et al., 2012). They found that animals treated with vitamin D had decreased retinal expression of VEGF and TGF- β 1. Histological examination also suggested that vitamin D had a protective effect in the retinas of these rats. These combined studies suggest that vitamin D status could be important in the prevention of DR, particularly proliferative retinopathy. Further studies are needed to determine the mechanism of vitamin D protection and if it can directly inhibit neovascularization in this sight-threatening condition.

2.5. Uveitis

Uveitis is an inflammatory condition that affects the retina and uvea. Inflammation can be caused by an infectious agent or, in the majority of cases, is thought to be autoimmune in nature, driven by retinal antigen-specific T lymphocytes (Caspi, 2010). Because of its ability to dampen inflammation, influence T cell response, and its known ability to have suppressive actions in autoimmune conditions, vitamin D is a good candidate to examine in the context of this sight-threatening disease.

The most common form of uveitis, acute anterior uveitis (AAU), has been strongly associated with the human leukocyte antigen (HLA)-B27 gene (Chang et al., 2005; Suhler et al., 2003; Wakefield et al., 2011). In an interesting retrospective study, the association of a vitamin D hydroxylase gene polymorphism (CYP27B1 rs703842 A>G) with HLA-B27-positive AAU was examined (Steinwender et al., 2013). This study found that individuals with AAU were more likely to have this CYP27B1 variation than HLA-B27-positive controls. Other studies have demonstrated that the rs703842 A>G polymorphism results in lower levels of circulating 25D₃ (Orton et al., 2008). Therefore, Steinwender et al. (2013) suggested that these HLA-B27 positive individuals could have an even greater impairment in immune function when vitamin D metabolism is disrupted.

Behçet's disease is an inflammatory disease that involves multiple organs in the body but over half of patients develop uveitis (Yazici et al., 2007). In a prospective study on a Chinese population, polymorphisms in an enzyme necessary for vitamin D production, DHCR7 (7-dehydrocholesterol reductase), were associated with susceptibility to ocular Behçet's disease in particular, demonstrating another genetic variation linking vitamin D metabolism and uveitis (Fang et al., 2014).

Experimental autoimmune uveitis (EAU) is a mouse model of human autoimmune uveitis in which the immune response has been well characterized. In this model, oral vitamin D treatment both prevented the development of disease as well as attenuated retinal autoimmunity once induced (Tang et al., 2009). Importantly, vitamin D inhibited the Th17 response that is responsible for the retinal inflammation in this model, influencing T cell cytokine production and the priming ability of dendritic cells. In similar studies using human samples from patients with Behçet's disease, vitamin D treatment also inhibited Th17 cell differentiation (Tian et al., 2012). These studies provide evidence that vitamin D

supplementation could be beneficial not only during the active inflammatory condition but also for prevention of uveitis as well.

2.6. Ocular Surface Inflammation and Pathology

Vitamin D is known to affect cell differentiation. In the cornea, VDR knockout mice had smaller superficial squamous cell size, decreased total corneal thickness, and lower numbers of tight junctions than wild-type animals (Lu and Watsky, 2014; Elizondo et al., 2014). Additionally, VDR influenced cell diffusion coefficients within the cornea, possibly playing a role in gap junction communications and development in this ocular tissue (Lu and Watsky, 2014). Interestingly, the rate of epithelial wound healing was decreased in VDR knockout animals (Elizondo et al., 2014). Mucin packaging in conjunctival goblet cells was also altered in VDR-deficient mice, with lower amounts of mucin (Muc5AC) in these animals compared to wild-types (Paz et al., 2003). However, both mucin and wound closure differences seemed to be attributable to vitamin D's influence on calcium homeostasis, as restoring ionized calcium levels in the VDR knockout mice restored normal mucin packaging as well as healing rates in these studies.

Inflammation at the ocular surface must be carefully regulated during infection and injury to prevent loss of corneal opacity and tissue damage. Based on vitamin D's known ability to suppress inflammation and influence the immune response, several groups have studied the immunomodulatory role of vitamin D within the local context of the ocular surface. *In vivo* studies have demonstrated that vitamin D can be anti-inflammatory at the ocular surface. In a mouse model of injury, topical administration of 1,25D₃ to sutured mouse corneas inhibited Langerhans cell migration and maturation, and delayed neovascularization in the central cornea (Suzuki et al., 2000a). In a rat keratoplasty model, 1,25D₃ protected against corneal graft rejection, inhibiting the proinflammatory cytokines interleukin-1 alpha (IL-1 α) and tumor necrosis factor alpha (TNF α) (Dang et al., 2004).

In vitro, vitamin D appears to dampen the inflammatory response to infection. Treatment with vitamin D downregulated the expression of IL-1 β , IL-6 and IL-8 induced by *Pseudomonas aeruginosa* infection in human corneal epithelial cells (Xue et al., 2002). In a separate report, 1,25D₃ also inhibited IL-1 α production (Suzuki et al., 2000b) and we have shown that vitamin D reduces Toll-like receptor induced inflammatory cytokines in cultured epithelial cells (Reins RY, McDermott AM. Vitamin D attenuates Toll-like receptor 3 induced inflammation in human corneal epithelial cells. Invest Ophthalmol Vis Sci 2013; e-abstract 2067). In addition, both 1,25D₃ and 25D₃ augmented corneal epithelial barrier function through upregulation of the tight junction proteins occludin and ZO-1 (Yin et al., 2011). Vitamin D therefore has the potential to reverse the harmful effects to the corneal epithelial barrier during infection and protect against inflammatory conditions.

In a cross-sectional study examining male patients with dry eye syndrome, a condition that is accompanied by ocular surface inflammation (DEWS report, 2007), serum 25D₃ levels were not found to be associated with severity of disease clinically (Galor et al., 2014). However, higher serum vitamin D levels were significantly correlated with a decrease in subjective dry eye symptoms, as determined by the Dry Eye Questionnaire 5. In a case report it was observed that a vitamin D-deficient patient with corneal neuralgia had relief

from burning pain with vitamin D supplementation, 1,000 IU/day, while topical therapies and lubricants were not effective (Singman et al., 2013). Although this is only a single observation without extensive follow-up, vitamin D's protective effect on ocular surface pain would be interesting to pursue further.

2.7. Glaucoma

Gene expression studies identified vitamin D as having the potential to modulate genes involved in regulating both aqueous humor outflow and production, as well as the architecture of the trabecular meshwork, thereby influencing IOP. In both cultured mouse calvarial cells and rat intestinal mucosa, treatment with vitamin D modulated the expression of numerous genes involved in intraocular pressure (IOP) regulation (Kutuzova et al., 2012). Microarray analysis showed that 1,25D₃ decreased the expression of carbonic anhydrase I (CAI), angiotensin I converting enzyme (ACE), aquaporin 1 channel (AQP1), and various cytoskeletal and extracellular matrix genes such as actin alpha (ACTA1) and fibronectin I. 1,25D₃ also upregulated matrix metalloproteinases 3, 11, 13, and 14, as well as prostaglandin E receptor 4 for PGE2 (PTGER4), purinergic receptors P2Y and P2RY2, and chemokine (C-C motif) ligand 20 (CCL20).

As a result of these gene expression studies, Kutuzova et al. (2012) examined the effect of 1,25D₃ or an analog, 2-methylene-19-nor-(20S)-1 α ,25-dihydroxyvitamin D(3) on IOP in non-human primates. They demonstrated that topical 1,25D₃, administered twice daily (0.1–15 μ g 1,25D₃ or vehicle propylene glycol) reduced IOP in monkeys. Significantly, when 1,25D₃ was applied to one eye without nasolacrimal duct occlusion, IOP was lowered bilaterally. However, 1,25D₃ did not reduce aqueous humor production or effect uveoscleral outflow in this model. Therefore, the mechanism involved in this decrease in IOP still needs to be investigated with further studies.

A very early study suggested that vitamin D, introduced intramuscularly, could decrease IOP in humans (Guist and Steffen, 1953). However, in a case control and randomized controlled study, Krefting et al. examined the association between serum vitamin D levels, vitamin D supplementation, and IOP and they found no statistical difference in IOP levels between individuals in the lowest serum 25D₃ group versus the high serum 25D₃ group (Krefting et al., 2013). Additionally, there was no significant change in IOP in participants who received vitamin D oral supplements (20,000 IU twice per week) at the end of 6 months compared to placebo.

Examining the association between vitamin D status and risk for open-angle glaucoma (OAG), Yoo et al. performed multivariable logistic regression analyses using 6094 participants from the Fifth Korean National Health and Nutrition Examination Survey (Yoo et al., 2014). They found a significant relationship between serum 25D₃ levels and prevalence of OAG, with increased risk of disease particularly in participants in the lowest quintile of 25D₃. Additionally, unlike the findings of Krefting et al (2013), IOP was significantly linked to vitamin D levels. This apparent discrepancy could in part be due to differences in participant ethnicity (Caucasian versus South Korean), sample size, or the exclusion of participants with diagnosed disease in the Krefting study. Further

epidemiological studies need to be done to determine if vitamin D status is a risk factor for glaucoma.

3. Conclusions

Vitamin D is a multifunctional hormone, which not only affects calcium homeostasis, but plays a role in immune system regulation as well as cell growth and survival. Many tissues in the eye are able to both activate and respond to vitamin D, suggesting that vitamin D is a biologically relevant molecule to study throughout the eye. Epidemiological studies demonstrate that vitamin D levels and genetic variations influence the development of a wide range of pathologies, such as myopia, age-related macular degeneration, diabetic retinopathy, and uveitis. In addition, at the cellular level, vitamin D is able to reduce inflammatory mediators, enhance barrier function, and induce cell death of cancerous cells. These studies suggest that vitamin D plays a protective role in ocular health. It will therefore be exciting to follow further work, examining the benefits of vitamin D therapeutically in the eye.

Acknowledgements

This work was supported by NIH Grant EY13175 (AMM), UT/UH Training Grant T32 07024 (RYR), William C. Ezell Fellowship (RYR), and UH Friends of NSM Scholarship (RYR).

Abbreviations

VDR	vitamin D receptor
UVB	ultraviolet B radiation
25D₃	25-hydroxyvitamin D ₃
1,25D₃	1,25-dihydroxyvitamin D ₃
VDRE	vitamin D response element
SNP	single-nucleotide polymorphism
AMD	age-related macular degeneration
HTRA1	high-temperature requirement factor A1
DR	diabetic retinopathy
AAU	acute anterior uveitis
DHCR7	7-dehydrocholesterol reductase
EAU	experimental autoimmune uveitis
IOP	intraocular pressure

References

Adams JS, Hewison M. Extrarenal expression of the 25-hydroxyvitamin D-1-hydroxylase. Arch. Biochem. Biophys. 2012; 523:95–102. [PubMed: 22446158]

- Aksoy H, Akçay F, Kurtul N, Baykal O, Avci B. Serum 1,25 dihydroxy vitamin D (1,25(OH)₂D₃), 25 hydroxy vitamin D (25(OH)D) and parathormone levels in diabetic retinopathy. *Clin. Biochem.* 2000; 33:47–51. [PubMed: 10693986]
- Albert DM, Kumar A, Strugnell SA, Darjatmoko SR, Lokken JM, Lindstrom MJ, Damico CM, Patel S. Effectiveness of 1alpha-hydroxyvitamin D₂ in inhibiting tumor growth in a murine transgenic pigmented ocular tumor model. *Arch. Ophthalmol.* 2004; 122:1365–1369. [PubMed: 15364717]
- Albert DM, Marcus DM, Gallo JP, O'Brien JM. The antineoplastic effect of vitamin D in transgenic mice with retinoblastoma. *Invest. Ophthalmol. Vis. Sci.* 1992; 33:2354–2364. [PubMed: 1634333]
- Albert DM, Nickells RW, Gamm DM, Zimbric ML, Schlamp CL, Lindstrom MJ, Audo I. Vitamin D analogs, a new treatment for retinoblastoma: The first Ellsworth Lecture. *Ophthalmic Genet.* 2002; 23:137–156. [PubMed: 12324873]
- Albert DM, Plum LA, Yang W, Marcet M, Lindstrom MJ, Clagett-Dame M, DeLuca HF. Responsiveness of human retinoblastoma and neuroblastoma models to a non-calcemic 19-nor Vitamin D analog. *J. Steroid Biochem. Mol. Biol.* 2005; 97:165–172. [PubMed: 16055326]
- Albert DM, Scheef EA, Wang S, Mehraein F, Darjatmoko SR, Sorenson CM, Sheibani N. Calcitriol is a potent inhibitor of retinal neovascularization. *Invest. Ophthalmol. Vis. Sci.* 2007; 48:2327–2334.
- Alsalem JA, Patel D, Susarla R, Coca-Prados M, Bland R, Walker EA, Rauz S, Wallace GR. Characterization of vitamin d production by human ocular barrier cells. *Invest. Ophthalmol. Vis. Sci.* 2014; 55:2140–2147. [PubMed: 24576880]
- Annamaneni S, Bindu CH, Reddy KP, Vishnupriya S. Association of vitamin D receptor gene start codon (Fok1) polymorphism with high myopia. *Oman J. Ophthalmol.* 2011; 4:57–62. [PubMed: 21897619]
- Annweiler C, Milea D, Beauchet O. Dietary vitamin D and AMD. *Ophthalmology.* 2012; 119:1090–1091. author reply 1091. [PubMed: 22551613]
- Artaza JN, Norris KC. Vitamin D reduces the expression of collagen and key profibrotic factors by inducing an antifibrotic phenotype in mesenchymal multipotent cells. *J. Endocrinol.* 2009; 200:207–221. [PubMed: 19036760]
- Audo I, Darjatmoko SR, Schlamp CL, Lokken JM, Lindstrom MJ, Albert DM, Nickells RW. Vitamin D analogues increase p53, p21, and apoptosis in a xenograft model of human retinoblastoma. *Invest. Ophthalmol. Vis. Sci.* 2003; 44:4192–4199. [PubMed: 14507860]
- Bouillon R, Carmeliet G, Verlinden L, van Etten E, Verstuyf A, Luderer HF, Lieben L, Mathieu C, Demay M. Vitamin D and human health: lessons from vitamin D receptor null mice. *Endocr. Rev.* 2008; 29:726–776. [PubMed: 18694980]
- Bu an K, Ivanisevi M, Zemunik T, Boraska V, Skrabi V, Vatauvuk Z, Galetovi D, Znaor L. Retinopathy and nephropathy in type 1 diabetic patients--association with polymorphisms of vitamin D-receptor, TNF, Neuro-D and IL-1 receptor 1 genes. *Coll. Antropol.* 2009; (33 Suppl 2): 99–105. [PubMed: 20120526]
- Caspi RR. A look at autoimmunity and inflammation in the eye. *J. Clin. Invest.* 2010; 120:3073–3083. [PubMed: 20811163]
- Chang JH, McCluskey PJ, Wakefield D. Acute anterior uveitis and HLA-B27. *Surv. Ophthalmol.* 2005; 50:364–388. [PubMed: 15967191]
- Chen W, Xu W, Tao Q, Liu J, Li X, Gan X, Hu H, Lu Y. Meta-analysis of the association of the HTRA1 polymorphisms with the risk of age-related macular degeneration. *Exp. Eye Res.* 2009; 89:292–300. [PubMed: 19026638]
- Choi HS, Oh HJ, Choi H, Choi WH, Kim JG, Kim KM, Kim KJ, Rhee Y, Lim S-K. Vitamin D insufficiency in Korea--a greater threat to younger generation: the Korea National Health and Nutrition Examination Survey (KNHANES) 2008. *J. Clin. Endocrinol. Metab.* 2011; 96:643–651. [PubMed: 21190984]
- Choi JA, Han K, Park Y-M, La TY. Low serum 25-hydroxyvitamin d is associated with myopia in korean adolescents. *Invest. Ophthalmol. Vis. Sci.* 2014; 55:2041–2047. [PubMed: 24699557]
- Cohen SM, Saulenas AM, Sullivan CR, Albert DM. Further studies of the effect of vitamin D on retinoblastoma. Inhibition with 1,25-dihydroxycholecalciferol. *Arch. Ophthalmol.* 1988; 106:541–543. [PubMed: 3355424]

- Coleman HR, Chan C-C, Ferris FL 3rd, Chew EY. Age-related macular degeneration. *Lancet*. 2008; 372:1835–1845. [PubMed: 19027484]
- Dang S-T, Lu X-H, Zhou J, Bai L. [Effects of 1 α , 25-dihydroxyvitamin D₃ on the acute immune rejection and corneal neovascularization in high-risk penetrating keratoplasty in rats]. *1 Jun Yi Xue Xue Bao Acad. J. First Med. Coll. PLA*. 2004; 24:892–896. 903.
- Dawson DG, Gleiser J, Zimbric ML, Darjatmoko SR, Lindstrom MJ, Strugnell SA, Albert DM. Toxicity and dose-response studies of 1- α hydroxyvitamin D₂ in LH-beta-tag transgenic mice. *Ophthalmology*. 2003; 110:835–839. [PubMed: 12689912]
- Day S, Acquah K, Platt A, Lee PP, Mruthyunjaya P, Sloan FA. Association of vitamin D deficiency and age-related macular degeneration in medicare beneficiaries. *Arch. Ophthalmol*. 2012; 130:1070–1071. [PubMed: 22893083]
- Dewan A, Liu M, Hartman S, Zhang SS-M, Liu DTL, Zhao C, Tam POS, Chan WM, Lam DSC, Snyder M, Barnstable C, Pang CP, Hoh J. HTRA1 promoter polymorphism in wet age-related macular degeneration. *Science*. 2006; 314:989–992. [PubMed: 17053108]
- Dulhunty AF, Beard NA, Pouliquin P, Kimura T. Novel regulators of RyR Ca²⁺ release channels: insight into molecular changes in genetically-linked myopathies. *J. Muscle Res. Cell Motil*. 2006; 27:351–365. [PubMed: 16909197]
- Elizondo RA, Yin Z, Lu X, Watsky MA. Effect of vitamin d receptor knockout on cornea epithelium wound healing and tight junctions. *Invest. Ophthalmol. Vis. Sci*. 2014; 55:5245–5251. [PubMed: 25061117]
- Fang J, Hou S, Xiang Q, Qi J, Yu H, Shi Y, Zhou Y, Kijlstra A, Yang P. Polymorphisms in genetics of vitamin D metabolism confer susceptibility to ocular Behçet disease in a Chinese Han population. *Am. J. Ophthalmol*. 2014; 157:488–494.e6. [PubMed: 24184224]
- Frampton RJ, Omond SA, Eisman JA. Inhibition of human cancer cell growth by 1,25-dihydroxyvitamin D₃ metabolites. *Cancer Res*. 1983; 43:4443–4447. [PubMed: 6307514]
- French AN, Ashby RS, Morgan IG, Rose KA. Time outdoors and the prevention of myopia. *Exp. Eye Res*. 2013; 114:58–68. [PubMed: 23644222]
- Galor A, Gardener H, Pouyeh B, Feuer W, Florez H. Effect of a mediterranean dietary pattern and vitamin d levels on dry eye syndrome. *Cornea*. 2014; 33:437–441. [PubMed: 24622300]
- Golan S, Shalev V, Treister G, Chodick G, Loewenstein A. Reconsidering the connection between vitamin D levels and age-related macular degeneration. *Eye*. 2011; 25:1122–1129. [PubMed: 21818133]
- Graffe A, Beauchet O, Fantino B, Milea D, Annweiler C. Vitamin d and macular thickness in the elderly: an optical coherence tomography study. *Invest. Ophthalmol. Vis. Sci*. 2014; 55:5298–5303. [PubMed: 25028353]
- Graffe A, Milea D, Annweiler C, Beauchet O, Mauget-Fayssse M, Beauchet O, Kodjikian L, Milea D. Association between hypovitaminosis D and late stages of age-related macular degeneration: a case-control study. *J. Am. Geriatr. Soc*. 2012; 60:1367–1369. [PubMed: 22788394]
- Gröber U, Spitz J, Reichrath J, Kisters K, Holick MF. Vitamin D: Update 2013: From rickets prophylaxis to general preventive healthcare. *Dermatoendocrinol*. 2013; 5:331–347. [PubMed: 24516687]
- Gross C, Eccleshall TR, Malloy PJ, Villa ML, Marcus R, Feldman D. The presence of a polymorphism at the translation initiation site of the vitamin D receptor gene is associated with low bone mineral density in postmenopausal Mexican-American women. *J. Bone Miner. Res*. 1996; 11:1850–1855. [PubMed: 8970885]
- Guggenheim JA, Northstone K, McMahon G, Ness AR, Deere K, Mattocks C, Pourcain BS, Williams C. Time outdoors and physical activity as predictors of incident myopia in childhood: a prospective cohort study. *Invest. Ophthalmol. Vis. Sci*. 2012; 53:2856–2865. [PubMed: 22491403]
- Guggenheim JA, Williams C, Northstone K, Howe LD, Tilling K, St Pourcain B, McMahon G, Lawlor DA. Does vitamin d mediate the protective effects of time outdoors on myopia? Findings from a prospective birth cohort. *Invest. Ophthalmol. Vis. Sci*. 2014; 55:8550–8558. [PubMed: 25406278]
- Guist G, Steffen C. [Application and mechanism of high dosage of vitamin D therapy of glaucoma]. *Klin. Monatsblätter Für Augenheilkd. Für Augenärztl. Fortbild*. 1953; 123:555–568.

- Halder SK, Goodwin JS, Al-Hendy A. 1,25-Dihydroxyvitamin D3 reduces TGF-beta3-induced fibrosis-related gene expression in human uterine leiomyoma cells. *J. Clin. Endocrinol. Metab.* 2011; 96:E754–E762. [PubMed: 21289245]
- Holick MF. Vitamin D deficiency. *N. Engl. J. Med.* 2007; 357:266–281. [PubMed: 17634462]
- Holick MF, Binkley NC, Bischoff-Ferrari HA, Gordon CM, Hanley DA, Heaney RP, Murad MH, Weaver CM. Endocrine Society. Evaluation, treatment, and prevention of vitamin D deficiency: an Endocrine Society clinical practice guideline. *J. Clin. Endocrinol. Metab.* 2011; 96:1911–1930. [PubMed: 21646368]
- Institute of Medicine (US) Committee to Review Dietary Reference Intakes for Vitamin D and Calcium. Dietary Reference Intakes for Calcium and Vitamin D. The National Academies Collection: Reports funded by National Institutes of Health. Washington (DC): National Academies Press (US); 2011.
- Isik S, Ozuguz U, Tutuncu YA, Erden G, Berker D, Acar K, Aydin Y, Akbaba G, Helvacı N, Guler S. Serum transforming growth factor-beta levels in patients with vitamin D deficiency. *Eur. J. Intern. Med.* 2012; 23:93–97. [PubMed: 22153539]
- Iyengar SK, Song D, Klein BEK, Klein R, Schick JH, Humphrey J, Millard C, Liptak R, Russo K, Jun G, Lee KE, Fijal B, Elston RC. Dissection of genomewide-scan data in extended families reveals a major locus and oligogenic susceptibility for age-related macular degeneration. *Am. J. Hum. Genet.* 2004; 74:20–39. [PubMed: 14691731]
- Johnson JA, Grande JP, Roche PC, Campbell RJ, Kumar R. Immuno-localization of the calcitriol receptor, calbindin-D28k and the plasma membrane calcium pump in the human eye. *Curr. Eye Res.* 1995; 14:101–108. [PubMed: 7539352]
- Jones G, Prosser DE, Kaufmann M. Cytochrome P450-mediated metabolism of vitamin D. *J. Lipid Res.* 2014; 55:13–31. [PubMed: 23564710]
- Jurutka PW, Whitfield GK, Hsieh JC, Thompson PD, Haussler CA, Haussler MR. Molecular nature of the vitamin D receptor and its role in regulation of gene expression. *Rev. Endocr. Metab. Disord.* 2001; 2:203–216. [PubMed: 11705326]
- Kamen DL, Tangpricha V. Vitamin D and molecular actions on the immune system: modulation of innate and autoimmunity. *J. Mol. Med.* 2010; 88:441–450. [PubMed: 20119827]
- Kaur H, Donaghue KC, Chan AK, Benitez-Aguirre P, Hing S, Lloyd M, Cusumano J, Pryke A, Craig ME. Vitamin D deficiency is associated with retinopathy in children and adolescents with type 1 diabetes. *Diabetes Care.* 2011; 34:1400–1402. [PubMed: 21515836]
- Kennel KA, Drake MT, Hurley DL. Vitamin D deficiency in adults: when to test and how to treat. *Mayo Clin. Proc.* 2010; 85:752–757. quiz 757-758. [PubMed: 20675513]
- Kift R, Berry JL, Vail A, Durkin MT, Rhodes LE, Webb AR. Lifestyle factors including less cutaneous sun exposure contribute to starkly lower vitamin D levels in U.K. South Asians compared with the white population. *Br. J. Dermatol.* 2013; 169:1272–1278. [PubMed: 23855783]
- Kim EC, Han K, Jee D. Inverse relationship between high blood 25-hydroxyvitamin D and late stage of age-related macular degeneration in a representative Korean population. *Invest. Ophthalmol. Vis. Sci.* 2014; 55:4823–4831. [PubMed: 25015360]
- Kim S, Shevde NK, Pike JW. 1,25-Dihydroxyvitamin D3 stimulates cyclic vitamin D receptor/retinoid X receptor DNA-binding, co-activator recruitment, and histone acetylation in intact osteoblasts. *J. Bone Miner. Res.* 2005; 20:305–317. [PubMed: 15647825]
- Krefting EA, Jorde R, Christoffersen T, Grimnes G. Vitamin D and intraocular pressure -results from a case-control and an intervention study. *Acta Ophthalmol.* 2013; 92:345–349. [PubMed: 23575211]
- Krishnan AV, Trump DL, Johnson CS, Feldman D. The role of vitamin D in cancer prevention and treatment. *Endocrinol. Metab. Clin. North Am.* 2010; 39:401–418. table of contents. [PubMed: 20511060]
- Kulkarni AD, van Ginkel PR, Darjatmoko SR, Lindstrom MJ, Albert DM. Use of combination therapy with cisplatin and calcitriol in the treatment of Y-79 human retinoblastoma xenograft model. *Br. J. Ophthalmol.* 2009; 93:1105–1108. [PubMed: 19336429]
- Kutuzova GD, Gabelt BT, Kiland JA, Hennes-Beann EA, Kaufman PL, DeLuca HF. 1 α ,25-Dihydroxyvitamin D(3) and its analog, 2-methylene-19-nor-(20S)-1 α ,25-dihydroxyvitamin D(3)

- (2MD), suppress intraocular pressure in non-human primates. *Arch. Biochem. Biophys.* 2012; 518:53–60. [PubMed: 22198282]
- Lee V, Rekhi E, Hoh Kam J, Jeffery G. Vitamin D rejuvenates aging eyes by reducing inflammation, clearing amyloid beta and improving visual function. *Neurobiol. Aging.* 2012; 33:2382–2389. [PubMed: 22217419]
- Lee YA, Kim HY, Hong H, Kim JY, Kwon HJ, Shin CH, Yang SW. Risk factors for low vitamin D status in Korean adolescents: the Korea National Health and Nutrition Examination Survey (KNHANES) 2008–2009. *Public Health Nutr.* 2014; 17:764–771. [PubMed: 23462341]
- Leysens C, Verlinden L, Verstuyf A. Antineoplastic effects of 1,25(OH)2D3 and its analogs in breast, prostate and colorectal cancer. *Endocr. Relat. Cancer.* 2013; 20:R31–R47. [PubMed: 23319494]
- Lin Y, Ubels JL, Schotanus MP, Yin Z, Pintea V, Hammock BD, Watsky MA. Enhancement of vitamin D metabolites in the eye following vitamin D3 supplementation and UV-B irradiation. *Curr. Eye Res.* 2012; 37:871–878. [PubMed: 22632164]
- Lu X, Watsky MA. Effects of Vitamin D Receptor Knockout on Cornea Epithelium Gap Junctions. *Invest. Ophthalmol. Vis. Sci.* 2014
- Millen AE, Volland R, Sondel SA, Parekh N, Horst RL, Wallace RB, Hageman GS, Chappell R, Blodi BA, Klein ML, Gehrs KM, Sarto GE, Mares JA. CAREDS Study Group. Vitamin D status and early age-related macular degeneration in postmenopausal women. *Arch. Ophthalmol.* 2011; 129:481–489. [PubMed: 21482873]
- Mithal A, Wahl DA, Bonjour J-P, Burckhardt P, Dawson-Hughes B, Eisman JA, El-Hajj Fuleihan G, Josse RG, Lips P, Morales-Torres J. IOF Committee of Scientific Advisors (CSA) Nutrition Working Group. Global vitamin D status and determinants of hypovitaminosis D. *Osteoporos. Int. J. Establ. Result Coop. Eur. Found. Osteoporos. Natl. Osteoporos. Found. USA.* 2009; 20:1807–1820.
- Morrison MA, Silveira AC, Huynh N, Jun G, Smith SE, Zacharaki F, Sato H, Loomis S, Andreoli MT, Adams SM, Radeke MJ, Jelcick AS, Yuan Y, Tsiloulis AN, Chatzoulis DZ, Silvestri G, Kotoula MG, Tsiroli EE, Hollis BW, Chen R, Haider NB, Miller JW, Farrer LA, Hageman GS, Kim IK, Schaumberg DA, DeAngelis MM. Systems biology-based analysis implicates a novel role for vitamin D metabolism in the pathogenesis of age-related macular degeneration. *Hum. Genomics.* 2011; 5:538–568. [PubMed: 22155603]
- Mutti DO. Vitamin d may reduce the prevalence of myopia in korean adolescents. *Invest. Ophthalmol. Vis. Sci.* 2014;55. [PubMed: 24222300]
- Mutti DO, Cooper ME, Dragan E, Jones-Jordan LA, Bailey MD, Marazita ML, Murray JC, Zadnik K. CLEERE Study Group. Vitamin D receptor (VDR) and group-specific component (GC, vitamin D-binding protein) polymorphisms in myopia. *Invest. Ophthalmol. Vis. Sci.* 2011; 52:3818–3824. [PubMed: 21357399]
- Mutti DO, Marks AR. Blood levels of vitamin D in teens and young adults with myopia. *Optom. Vis. Sci.* 2011; 88:377–382. [PubMed: 21258262]
- Nagakura K, Abe E, Suda T, Hayakawa M, Nakamura H, Tazaki H. Inhibitory effect of 1 alpha,25-dihydroxyvitamin D3 on the growth of the renal carcinoma cell line. *Kidney Int.* 1986; 29:834–840. [PubMed: 3012186]
- Nussenblatt RB, Liu B, Li Z. Age-related macular degeneration: an immunologically driven disease. *Curr. Opin. Investig. Drugs.* 2000. 2009; 10:434–442.
- Orton S-M, Morris AP, Herrera BM, Ramagopalan SV, Lincoln MR, Chao MJ, Vieth R, Sadovnick AD, Ebers GC. Evidence for genetic regulation of vitamin D status in twins with multiple sclerosis. *Am. J. Clin. Nutr.* 2008; 88:441–447. [PubMed: 18689381]
- Pahl L, Schubert S, Skawran B, Sandbothe M, Schmidtke J, Stuhmann M. 1,25-Dihydroxyvitamin D decreases HTRA1 promoter activity in the rhesus monkey--a plausible explanation for the influence of vitamin D on age-related macular degeneration? *Exp. Eye Res.* 2013; 116:234–239. [PubMed: 24076413]
- Parekh N, Chappell RJ, Millen AE, Albert DM, Mares JA. Association between vitamin D and age-related macular degeneration in the Third National Health and Nutrition Examination Survey, 1988 through 1994. *Arch. Ophthalmol.* 2007; 125:661–669. [PubMed: 17502506]

- Payne JF, Ray R, Watson DG, Delille C, Rimler E, Cleveland J, Lynn MJ, Tangpricha V, Srivastava SK. Vitamin D insufficiency in diabetic retinopathy. *Endocr. Pract.* 2012; 18:185–193. [PubMed: 21940279]
- Paz HB, Tisdale AS, Danjo Y, Spurr-Michaud SJ, Argüeso P, Gipson IK. The role of calcium in mucin packaging within goblet cells. *Exp. Eye Res.* 2003; 77:69–75. [PubMed: 12823989]
- Petta S, Cammà C, Scazzone C, Tripodo C, Di Marco V, Bono A, Cabibi D, Licata G, Porcasi R, Marchesini G, Craxí A. Low vitamin D serum level is related to severe fibrosis and low responsiveness to interferon-based therapy in genotype 1 chronic hepatitis C. *Hepatology*. 2010; 51:1158–1167.
- Picotto G, Liaudat AC, Bohl L, Tolosa de Talamoni N. Molecular aspects of vitamin D anticancer activity. *Cancer Invest.* 2012; 30:604–614. [PubMed: 22963190]
- Plum LA, DeLuca HF. Vitamin D, disease and therapeutic opportunities. *Nat. Rev. Drug Discov.* 2010; 9:941–955. [PubMed: 21119732]
- Poon M, Craig ME, Kaur H, Cusumano J, Sasongko MB, Wong TY, Donaghue KC. Vitamin D deficiency is not associated with changes in retinal geometric parameters in young people with type 1 diabetes. *J. Diabetes Res.* 2013; 2013:280691. [PubMed: 23936865]
- Prietl B, Treiber G, Pieber TR, Amrein K. Vitamin D and immune function. *Nutrients.* 2013; 5:2502–2521. [PubMed: 23857223]
- Prosser DE, Jones G. Enzymes involved in the activation and inactivation of vitamin D. *Trends Biochem. Sci.* 2004; 29:664–673. [PubMed: 15544953]
- Ramirez AM, Wongtrakool C, Welch T, Steinmeyer A, Zügel U, Roman J. Vitamin D inhibition of pro-fibrotic effects of transforming growth factor beta1 in lung fibroblasts and epithelial cells. *J. Steroid Biochem. Mol. Biol.* 2010; 118:142–150. [PubMed: 19931390]
- Ren Z, Li W, Zhao Q, Ma L, Zhu J. The impact of 1,25-dihydroxy vitamin D3 on the expressions of vascular endothelial growth factor and transforming growth factor- β_1 in the retinas of rats with diabetes. *Diabetes Res. Clin. Pract.* 2012; 98:474–480. [PubMed: 23089551]
- Rose KA, Morgan IG, Ip J, Kifley A, Huynh S, Smith W, Mitchell P. Outdoor activity reduces the prevalence of myopia in children. *Ophthalmology.* 2008; 115:1279–1285. [PubMed: 18294691]
- Sabet SJ, Darjatmoko SR, Lindstrom MJ, Albert DM. Antineoplastic effect and toxicity of 1,25-dihydroxy-16-ene-23-yne-vitamin D3 in athymic mice with Y-79 human retinoblastoma tumors. *Arch. Ophthalmol.* 1999; 117:365–370. [PubMed: 10088815]
- Saulenas AM, Cohen SM, Key LL, Winter C, Albert DM. Vitamin D and retinoblastoma. The presence of receptors and inhibition of growth in vitro. *Arch. Ophthalmol.* 1988; 106:533–535. [PubMed: 2833210]
- Schauber J, Gallo RL. The vitamin D pathway: a new target for control of the skin's immune response? *Exp. Dermatol.* 2008; 17:633–639. [PubMed: 18573153]
- Seddon JM, Reynolds R, Shah HR, Rosner B. Smoking, dietary betaine, methionine, and vitamin D in monozygotic twins with discordant macular degeneration: epigenetic implications. *Ophthalmology.* 2011; 118:1386–1394. [PubMed: 21620475]
- Seddon JM, Santangelo SL, Book K, Chong S, Cote J. A genome-wide scan for age-related macular degeneration provides evidence for linkage to several chromosomal regions. *Am. J. Hum. Genet.* 2003; 73:780–790. [PubMed: 12945014]
- Sherwin JC, Mackey DA. Update on the epidemiology and genetics of myopic refractive error. *Expert Rev. Ophthalmol.* 2013; 8:63–87.
- Sherwin JC, Reacher MH, Keogh RH, Khawaja AP, Mackey DA, Foster PJ. The association between time spent outdoors and myopia in children and adolescents: a systematic review and meta-analysis. *Ophthalmology.* 2012; 119:2141–2151. [PubMed: 22809757]
- Shokravi MT, Marcus DM, Alroy J, Egan K, Saornil MA, Albert DM. Vitamin D inhibits angiogenesis in transgenic murine retinoblastoma. *Invest. Ophthalmol. Vis. Sci.* 1995; 36:83–87. [PubMed: 7529753]
- Shternfeld IS, Lasudry JG, Chappell RJ, Darjatmoko SR, Albert DM. Antineoplastic effect of 1,25-dihydroxy-16-ene-23-yne-vitamin D3 analogue in transgenic mice with retinoblastoma. *Arch. Ophthalmol.* 1996; 114:1396–1401. [PubMed: 8906031]

- Singh A, Falk MK, Subhi Y, Sørensen TL. The association between plasma 25-hydroxyvitamin D and subgroups in age-related macular degeneration: a cross-sectional study. *PloS One*. 2013; 8:e70948. [PubMed: 23923033]
- Singman EL, Poon D, Jun AS. Putative corneal neuralgia responding to vitamin d supplementation. *Case Rep. Ophthalmol*. 2013; 4:105–108. [PubMed: 24163676]
- Steinwender G, Lindner E, Weger M, Plainer S, Renner W, Ardjomand N, El-Shabrawi Y. Association between polymorphism of the vitamin D metabolism gene CYP27B1 and HLA-B27-associated uveitis. Is a state of relative immunodeficiency pathogenic in HLA B27-positive uveitis? *PLoS One*. 2013; 8:e62244. [PubMed: 23614044]
- Suárez F, Jockovich M-E, Hernandez E, Feuer W, Parel J-M, Murray TG. Paclitaxel in the Treatment of Retinal Tumors of LH beta-Tag Murine Transgenic Model of Retinoblastoma. *Invest. Ophthalmol. Vis. Sci*. 2007; 48:3437–3440. [PubMed: 17652710]
- Suhler EB, Martin TM, Rosenbaum JT. HLA-B27-associated uveitis: overview and current perspectives. *Curr. Opin. Ophthalmol*. 2003; 14:378–383. [PubMed: 14615643]
- Suzuki T, Sano Y, Kinoshita S. Effects of 1alpha,25-dihydroxyvitamin D3 on Langerhans cell migration and corneal neovascularization in mice. *Invest. Ophthalmol. Vis. Sci*. 2000a; 41:154–158. [PubMed: 10634615]
- Suzuki T, Sano Y, Sotozono C, Kinoshita S. Regulatory effects of 1alpha,25-dihydroxyvitamin D(3) on cytokine production by human corneal epithelial cells. *Curr. Eye Res*. 2000b; 20:127–130. [PubMed: 10617914]
- Szyszkka P, Zmijewski MA, Slominski AT. New vitamin D analogs as potential therapeutics in melanoma. *Expert Rev. Anticancer Ther*. 2012; 12:585–599. [PubMed: 22594894]
- Tang J, Zhou R, Luger D, Zhu W, Silver PB, Grajewski RS, Su S-B, Chan C-C, Adorini L, Caspi RR. Calcitriol suppresses antiretinal autoimmunity through inhibitory effects on the Th17 effector response. *J. Immunol*. 1950. 2009; 182:4624–4632.
- Taverna MJ, Selam J-L, Slama G. Association between a protein polymorphism in the start codon of the vitamin D receptor gene and severe diabetic retinopathy in C-peptide-negative type 1 diabetes. *J. Clin. Endocrinol. Metab*. 2005; 90:4803–4808. [PubMed: 15899948]
- Taverna MJ, Sola A, Guyot-Argenton C, Pacher N, Bruzzo F, Slama G, Reach G, Selam J-L. Taq I polymorphism of the vitamin D receptor and risk of severe diabetic retinopathy. *Diabetologia*. 2002; 45:436–442. [PubMed: 11914750]
- The definition and classification of dry eye disease: report of the Definition and Classification Subcommittee of the International Dry Eye WorkShop (2007). *Ocul. Surf*. 2007; 5:75–92. [PubMed: 17508116]
- Tian Y, Wang C, Ye Z, Xiao X, Kijlstra A, Yang P. Effect of 1,25-dihydroxyvitamin D3 on Th17 and Th1 response in patients with Behçet's disease. *Invest. Ophthalmol. Vis. Sci*. 2012; 53:6434–6441.
- Tong Y, Liao J, Zhang Y, Zhou J, Zhang H, Mao M. LOC387715/HTRA1 gene polymorphisms and susceptibility to age-related macular degeneration: A HuGE review and meta-analysis. *Mol. Vis*. 2010; 16:1958–1981. [PubMed: 21031019]
- van Etten E, Verlinden L, Giulietti A, Ramos-Lopez E, Branisteanu DD, Ferreira GB, Overbergh L, Verstuyf A, Bouillon R, Roep BO, Badenhoop K, Mathieu C. The vitamin D receptor gene FokI polymorphism: functional impact on the immune system. *Eur. J. Immunol*. 2007; 37:395–405. [PubMed: 17274004]
- Verhoeff FH. Retinoblastoma undergoing spontaneous regression. Calcifying agent suggested in treatment of retinoblastoma. *Am. J. Ophthalmol*. 1966; 62:573–574. [PubMed: 5922000]
- Verstappen A, Parmentier M, Chirnoaga M, Lawson DE, Pasteels JL, Pochet R. Vitamin D-dependent calcium binding protein immunoreactivity in human retina. *Ophthalmic Res*. 1986; 18:209–214. [PubMed: 3534678]
- Wagner N, Wagner K-D, Schley G, Badiali L, Theres H, Scholz H. 1,25-dihydroxyvitamin D3-induced apoptosis of retinoblastoma cells is associated with reciprocal changes of Bcl-2 and bax. *Exp. Eye Res*. 2003; 77:1–9. [PubMed: 12823982]
- Wakefield D, Chang JH, Amjadi S, Maconochie Z, Abu El-Asrar A, McCluskey P. What is new HLA-B27 acute anterior uveitis? *Ocul. Immunol. Inflamm*. 2011; 19:139–144. [PubMed: 21428757]

- Wang T-T, Tavera-Mendoza LE, Laperriere D, Libby E, MacLeod NB, Nagai Y, Bourdeau V, Konstorum A, Lallemand B, Zhang R, Mader S, White JH. Large-scale in silico and microarray-based identification of direct 1,25-dihydroxyvitamin D3 target genes. *Mol. Endocrinol.* 2005; 19:2685–2695. [PubMed: 16002434]
- Wang Y, Wang VM, Chan C-C. The role of anti-inflammatory agents in age-related macular degeneration (AMD) treatment. *Eye.* 2011; 25:127–139. [PubMed: 21183941]
- White JH. Vitamin D signaling, infectious diseases, and regulation of innate immunity. *Infect. Immun.* 2008; 76:3837–3843. [PubMed: 18505808]
- Wilkerson CL, Darjatmoko SR, Lindstrom MJ, Albert DM. Toxicity and dose-response studies of 1,25-(OH)₂-16-ene-23-yne vitamin D3 in transgenic mice. *Clin. Cancer Res.* 1998; 4:2253–2256. [PubMed: 9748146]
- Windle JJ, Albert DM, O'Brien JM, Marcus DM, Disteché CM, Bernards R, Mellon PL. Retinoblastoma in transgenic mice. *Nature.* 1990; 343:665–669. [PubMed: 1689463]
- Xue M-L, Zhu H, Thakur A, Willcox M. 1 alpha,25-Dihydroxyvitamin D3 inhibits pro-inflammatory cytokine and chemokine expression in human corneal epithelial cells colonized with *Pseudomonas aeruginosa*. *Immunol. Cell Biol.* 2002; 80:340–345. [PubMed: 12121222]
- Yang Z, Camp NJ, Sun H, Tong Z, Gibbs D, Cameron DJ, Chen H, Zhao Y, Pearson E, Li X, Chien J, Dewan A, Harmon J, Bernstein PS, Shridhar V, Zabriskie NA, Hoh J, Howes K, Zhang K. A variant of the HTRA1 gene increases susceptibility to age-related macular degeneration. *Science.* 2006; 314:992–993. [PubMed: 17053109]
- Yazar S, Hewitt AW, Black LJ, McKnight CM, Mountain JA, Sherwin JC, Oddy WH, Coroneo MT, Lucas RM, Mackey DA. Myopia is associated with lower vitamin D status in young adults. *Invest. Ophthalmol. Vis. Sci.* 2014; 55:4552–4559. [PubMed: 24970253]
- Yazici H, Fresko I, Yurdakul S. Behçet's syndrome: disease manifestations, management, and advances in treatment. *Nat. Clin. Pract. Rheumatol.* 2007; 3:148–155. [PubMed: 17334337]
- Yin Z, Pintea V, Lin Y, Hammock BD, Watsky MA. Vitamin D enhances corneal epithelial barrier function. *Invest. Ophthalmol. Vis. Sci.* 2011; 52:7359–7364. [PubMed: 21715350]
- Yoon K-C, Mun G-H, Kim S-D, Kim S-H, Kim CY, Park KH, Park YJ, Baek S-H, Song SJ, Shin JP, Yang S-W, Yu S-Y, Lee JS, Lim KH, Park H-J, Pyo E-U, Yang J-E, Kim Y-T, Oh K-W, Kang SW. Prevalence of Eye Diseases in South Korea: Data from the Korea National Health and Nutrition Examination Survey 2008–2009. *Korean J. Ophthalmol.* 2011; 25:421. [PubMed: 22131780]
- Yoo TK, Oh E, Hong S. Is vitamin D status associated with open-angle glaucoma? A cross-sectional study from South Korea. *Public Health Nutr.* 2014; 17:833–843. [PubMed: 24476947]

Highlights

- Vitamin D deficiency is associated with development of various ocular pathologies.
- Genetic variations in vitamin D pathways genes are associated with disease risk.
- Ocular cells express vitamin D-related genes and can activate vitamin D.
- Vitamin D treatment is protective in animal models of ocular disease.
- *In vitro* studies suggest that vitamin D dampens inflammatory events in the eye.

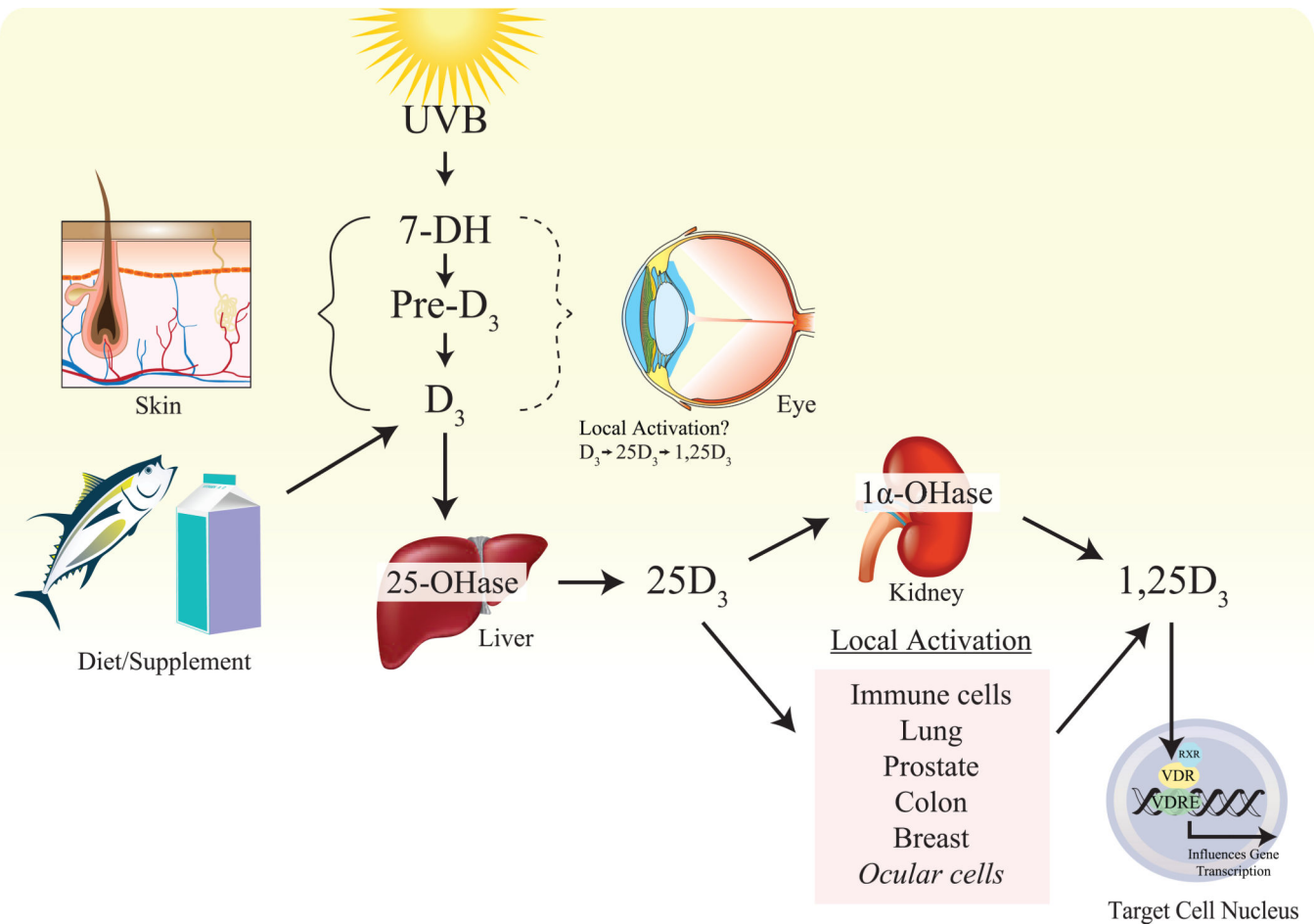


Figure 1.

Vitamin D₃ production and activation. UVB from sunlight penetrates the skin, converting a cholesterol precursor, 7-dehydrocholesterol (7-DH), to pre-vitamin D₃ (pre-D₃), which then isomerizes to form vitamin D₃ (D₃). Recent evidence suggests that ocular surface cells also produce vitamin D₃ de novo when exposed to UVB. Vitamin D₃ must undergo two enzymatic steps to form the biologically active hormone. The skin, and possibly the cornea, is able to activate and utilize vitamin D₃ locally. However, the majority of vitamin D₃ is transported to the liver, where the 25-hydroxylases (25-OHase) CYP2R1 and CYP27A1, catalyze the formation of 25-hydroxyvitamin D₃ (25D₃), the major circulating form. Activation of 25D₃ traditionally occurs in the kidney through the 1α-hydroxylase, CYP27B1 (1α-OHase), although many extra-renal tissues and cell types are also able to activate 25D₃, including cells of the eye. The functionally active 1α-dihydroxyvitamin D₃ (1,25D₃) then binds to its nuclear hormone receptor, VDR, in target cells, influencing gene transcription through interactions with vitamin D response elements (VDRE).

Table 1

Summary of studies examining various aspects of vitamin D as it relates to ocular disease, health, and the basic biology of the eye.

Vitamin D Status	Low serum 25D ₃ levels associated with disease risk; or high 25D ₃ levels associated with decreased disease prevalence	Myopia ^a Age-related Macular Degeneration ^b Diabetic Retinopathy ^c Dry eye syndrome ^d
Genetic Variations^e	Gene polymorphisms associated with disease (VDR, CYP24A1, CYP27B1, DHCR7)	Myopia ^a Age-related Macular Degeneration ^b Diabetic Retinopathy ^c Uveitis ^f
Treatment/Supplementation	Improvement of disease or pathology with either systemic or local vitamin D treatment	Retinoblastoma (mouse) ^g Choroidal Melanoma (mouse) ^g Retinal aging (mouse) ^b Ischemic retinopathy (mouse) ^b Type 2 diabetic retinopathy (rat) ^c Experimental autoimmune uveitis (mouse) ^f Corneal injury (mouse) ^d Corneal transplantation (rat) ^d Corneal neuralgia (human case report) ^d Intraocular pressure (non-human primate) ^h
In vitro Cell Studies	Expression of vitamin D pathway components and/or biological effect of vitamin D treatment	Corneal epithelial cells ^{di} Lens epithelial cells ⁱ Corneal endothelial cells ⁱ Scleral fibroblasts ⁱ Nonpigmented ciliary body epithelial cells ⁱ Adult retinal pigment epithelial cells ^{bi} Ganglion cell layer ⁱ Retinal photoreceptors ⁱ Retinoblastoma cells (Y79, Weri-RB1) ^g

^aSee 2.1. Myopia

^bSee 2.3. Age-Related Macular Degeneration

^cSee 2.4. Diabetic Retinopathy

^dSee 2.6. Ocular Surface Inflammation and Pathology

^eTable 2

^fSee 2.5. Uveitis

^gSee 2.2. Retinoblastoma

^hSee 2.7. Glaucoma

ⁱSee 1. Introduction

Author Manuscript

Author Manuscript

Author Manuscript

Author Manuscript

Table 2

Genetic polymorphisms in vitamin D pathway genes and their known associations with ocular diseases.

Pathology	Gene; variation	Association	Publication
Myopia	VDR; <i>FOKI</i>	None with high myopia Increased frequency of f allele in myopic females	Annamaneni et al., 2011
	VDR; rs2853559 rs2239182 rs3819545 rs2853559	Associated with Caucasian subjects >-0.75 D myopia in both eyes Associated with Caucasian subjects between - 0.75 D and -4.00 D	Mutti et al., 2011
AMD	CYP24A1; rs6127118 rs2762934	Associated with neo-vascular AMD in family- based cohort	Morrison et al., 2011
	rs1570669 rs1570670 rs2274130 rs2296239 rs4809957 VDR; rs2189480	Significantly associated with AMD in meta- analysis Associated with neo-vascular AMD in family-based cohort; not significant in all AMD subtypes	
Diabetic Retinopathy	VDR; <i>FOKI</i>	Decreased incidence of advanced DR in type 1 diabetics	Taverna et al., 2013
	VDR; BsmI	Associated with DR in type 1 diabetics	Bucan et al., 2009
	VDR; Taq I	Frequency of TT, wildtype genotype, was lower in type 1 patients with severe DR	Taverna et al., 2002
Uveitis	CYP27B1; rs703842 A>G	Increased frequency in HLA-B27-positive AAU patients compared to controls	Steinwender et al., 2013
	DHCR7; rs12785878	Associated with ocular Behçet's disease patients	Fang et al., 2013