

Accepted Manuscript

Title: Spot the silent sufferers: A call for clinical diagnostic criteria for solar and nutritional osteomalacia

Authors: Suma Uday, Wolfgang Högler

PII: S0960-0760(18)30542-9
DOI: <https://doi.org/10.1016/j.jsbmb.2019.01.004>
Reference: SBMB 5286



To appear in: *Journal of Steroid Biochemistry & Molecular Biology*

Received date: 2 September 2018
Revised date: 2 January 2019
Accepted date: 12 January 2019

Please cite this article as: Uday S, Högler W, Spot the silent sufferers: A call for clinical diagnostic criteria for solar and nutritional osteomalacia, *Journal of Steroid Biochemistry and Molecular Biology* (2019), <https://doi.org/10.1016/j.jsbmb.2019.01.004>

This is a PDF file of an unedited manuscript that has been accepted for publication. As a service to our customers we are providing this early version of the manuscript. The manuscript will undergo copyediting, typesetting, and review of the resulting proof before it is published in its final form. Please note that during the production process errors may be discovered which could affect the content, and all legal disclaimers that apply to the journal pertain.

Title:**Spot the silent sufferers: A call for clinical diagnostic criteria for solar and nutritional osteomalacia**

Suma Uday^{1,2}, Wolfgang Högler^{2,3}

1. Department of Diabetes and Endocrinology, Birmingham Women's and Children's Hospital, Birmingham, UK
2. Institute of Metabolism and Systems Research, University of Birmingham, Birmingham, UK
3. Department of Paediatrics and Adolescent Medicine, Johannes Kepler University, Linz, Austria

Corresponding author:

Prof Dr Wolfgang Högler
Department of Paediatrics and Adolescent Medicine
Kepler University Hospital
Krankenhausstrasse 26-30
4020 Linz, Austria
Tel: +43 5768084 22001
Email: Wolfgang.hoegler@jku.at

Words: 2554

Figures: 2

Tables/Boxes: 2

Highlights (85 words):

- The burden of “nutritional” rickets due to solar vitamin D and dietary calcium deficiency is increasing worldwide. Nutritional osteomalacia co-exists with rickets in children, but also affects adults and adolescents with closed epiphyses who mostly remain undiagnosed.
- Nutritional osteomalacia is a growing global public health concern and yet the true disease burden remains unexplored and neglected.
- There is a pressing need for non-invasive, clinical diagnostic criteria and studies exploring osteomalacia's true prevalence in vivo and post mortem in order to

inform public health policies relating to vitamin D/ calcium supplementation and food fortification.

ABSTRACT

Osteomalacia and rickets result from defective mineralization when the body is deprived of calcium. Globally, the main cause of osteomalacia is a lack of mineral supply for bone modeling and remodeling due to solar vitamin D and/or dietary calcium deficiency. Osteomalacia occurs when existing bone is replaced by unmineralized bone matrix (osteoid) during remodeling in children and adults, or when newly formed bone is not mineralized in time during modeling in children. Rickets occurs when hypomineralization affects the epiphyseal growth plate chondrocytes and adjacent bone metaphysis in growing children. Hence, osteomalacia co-exists with rickets in growing children. Several reports in the last decade highlight the resurgence of so-called “nutritional” rickets in the dark-skinned population living in high-income countries. However, very few studies have ever explored the hidden iceberg of nutritional osteomalacia in the population.

Rickets presents with hypocalcaemic (seizures, tetany, cardiomyopathy), or hypophosphataemic complications (leg bowing, knock knees, rachitic rosary, muscle weakness) and is diagnosed on radiographs (cupping and fraying of metaphyses). In contrast, osteomalacia lacks distinctive, non-invasive diagnostic laboratory or imaging criteria and the clinical presentation is non-specific (general fatigue, malaise, muscle weakness and pain). Hence, osteomalacia remains largely undiagnosed, as a hidden disease in millions of dark-skinned people who are at greatest risk. Radiographs may demonstrate Looser’s zone fractures in those most severely affected, however to date, osteomalacia remains a histological diagnosis requiring a bone biopsy. Biochemical features of high serum alkaline phosphatase (ALP), high

parathyroid hormone (PTH) with or without low 25 hydroxyvitamin D (25OHD) concentrations are common to both rickets and osteomalacia.

Here, we propose non-invasive diagnostic criteria for osteomalacia. We recommend a diagnosis of osteomalacia in the presence of high ALP, high PTH, low dietary calcium intake (<300 mg/day) and/or low serum 25OHD (<30 nmol/L). Presence of clinical symptoms (as above) or Looser's zone fractures should be used to reaffirm the diagnosis.

We call for further studies to explore the true prevalence of nutritional osteomalacia in various populations, specifically the Black and Asian ethnic groups, in order to identify the hidden disease burden and inform public health policies for vitamin D/calcium supplementation and food fortification.

Keywords: Bone modeling, remodeling, biopsy, micronutrient, malnutrition, nutrition, bone turnover, rickets, osteomalacia, osteoporosis

INTRODUCTION

Osteomalacia results from defective mineralization of pre-formed osteoid laid down by osteoblasts, and occurs due to lack of mineral supply (calcium and phosphate), often secondary to a lack of calcitriol (active vitamin D) which is required for intestinal calcium absorption. Osteomalacia affects humans from conception to grave. In growing young children, osteomalacia leads to leg bowing and is accompanied by growth plate disarray with metaphyseal swellings referred to as rickets [1]. Although osteomalacia/rickets can occur due to inherited or acquired disorders causing hypophosphataemia, or defects in calcitriol synthesis/action or in the vitamin D

metabolism pathway [1], the leading causes worldwide, by far, remain solar (vitamin D deficiency) and/or dietary (calcium deficiency) [2]. Whilst sunshine and diet are completely different environmental factors, common terminology still summarises these factors as “nutritional” which can lead to confusion.

‘Nutritional’ osteomalacia and rickets due to dietary calcium deficiency are endemic in populations with low calcium intake typical for many low and middle income countries [3,4]. Osteomalacia and rickets are also re-emerging in high income countries at high latitude (i.e. most of Europe) where restricted sunlight is the main cause, predominantly affecting the Black, Asian and Minority Ethnic (BAME) groups with dark skin [5,6]. Melanin absorbs natural solar Ultraviolet B (UVB) radiation thereby reducing the amount of vitamin D synthesised. Hence darker skin requires prolonged exposure to UVB compared to lighter skin to produce the same amount of vitamin D, and consequently the BAME population carries the highest risk of osteomalacia and rickets. However, subjects from any ethnic group will eventually develop vitamin D deficiency if they block sunlight (full body clothing, sunscreen, pollution, indoor living) or have no access to UVB containing sunlight (latitude), unless they take oral vitamin D supplements or fortified food. Hence many high income countries have National vitamin D supplementation and/or food fortification policies in place with major differences in implementation strategies and success at least in infants. Whilst the incidence of clinically evident nutritional rickets affecting children in high income countries is reported to be rising [7,8], the true prevalence of occult nutritional osteomalacia affecting both children and adults remain unidentified. Nutritional osteomalacia is the hidden body of the vitamin D deficiency iceberg which remains unexplored for several reasons including its insidious onset, non-specific clinical presentation and the lack of universally accepted diagnostic criteria. Those

affected largely go undiagnosed as evident by the extent of hidden biochemical osteomalacia in family members of infants presenting with hypocalcaemic dilated cardiomyopathy and rickets [6] and the incidental finding of widespread osteomalacia in adults at post-mortem [9]. Therefore, osteomalacia can be easily missed if the diagnosis is not considered and actively sought. Here, we highlight the pressing need for universal diagnostic criteria, studies exploring the true prevalence and public health prevention strategies for nutritional osteomalacia.

What is osteomalacia?

The term osteomalacia was originally used to describe softening of bones which resulted in crippling deformities [10]. The availability of in vivo tetracycline labelling for bone biopsy sampling enabled osteomalacia to be described as defective mineralization of osteoid. Osteomalacia occurs when resorbed bone is replaced by unmineralized bone matrix (osteoid) during the bone remodeling cycle (all humans), or wherever new bone is being laid down and not mineralized in time during bone modeling (growing children) [10].

How does osteomalacia differ from rickets and osteoporosis?

Rickets and osteomalacia have the same underlying pathological mechanism of defective mineralization due to lack of mineral supply. Whilst rickets affects the epiphyseal growth plate cartilage and adjacent bone metaphysis in growing children with open epiphyses, osteomalacia affects pre-formed osteoid in existing bone of both children and adults. Hence, osteomalacia always co-exists with rickets in children [1]. Although x-ray changes are only seen in the late stages of the disease process, rickets remains a radiological diagnosis. In contrast, whilst leg bowing is an obvious sign of osteomalacia, it cannot be diagnosed on radiographs and to date,

definitive diagnosis requires bone histomorphometry with tetracycline labelling (biopsy) [11,12].

Osteoporosis, on the other hand is not a bone mineralization defect, but a mass and structural defect leading to increased fragility. Osteoporosis occurs from reduced bone mass accrual in children or increased bone resorption in children and adults [13,14]. In adults, differentiating between osteoporosis and osteomalacia may be difficult since they may coexist when secondary hyperparathyroidism due to endemic vitamin D or calcium deficiency increases bone resorption [11,15]. A low bone mineral density (BMD) on a Dual Energy X-ray Absorptiometry (DXA) scan is noted in both conditions.

How does nutritional osteomalacia present and who is at risk?

The clinical presentation of osteomalacia is varied and depends on the age of presentation (**Figure 1**). Children, especially infants and adolescents, i.e. during phases of rapid growth, are most likely to be symptomatic due to high mineral demand in growing bones [16,17]. Infants are the most vulnerable group who present with life threatening hypocalcaemic complications such as seizures and tetany [18], heart failure secondary to dilated cardiomyopathy [19] and rarely cardiac death [6,19,20], as well as classical rickets signs. Bony deformities such as enlarged fontanelle, rachitic rosary, swollen joints are clinical signs of rickets and knock knees or bowed legs are clinical signs of the associated osteomalacia noted in infants or growing children. These signs do not develop in adults or adolescents after epiphyseal fusion, making the disease far less obvious in older age groups. Acute hypocalcaemic complications such as seizures are very rarely reported in adults [21]. However, it is not unusual for adults with osteomalacia to present to neurologists

with proximal muscle weakness [22,23] . Elderly and institutionalised individuals are likely to present with increased falls and fractures [24]. From a public health perspective, it is crucial to understand that clinical presentations of nutritional rickets or osteomalacia only represent the tip of the iceberg of widespread vitamin D and calcium deficiencies; the majority of the population suffer in silence as the hidden body of the deficiency iceberg remains unidentified (**Figure 1**). Post mortem studies have attempted to uncover the true burden of disease in children [20,25] using growth plate histology where nearly 70% of subjects showed histological evidence of rickets, although lacking in bone histomorphometric data [20,25]. An adult post-mortem study (n=675) from Germany reported histomorphometric evidence of nutritional osteomalacia in nearly 25% of subjects [9], associated with low 25 hydroxyvitamin D (25OHD) concentrations (<75 nmol/L),.

We emphasise that investigation of acutely presenting infants with rickets and osteomalacia should also include maternal investigations as the vitamin D deficient state is naturally passed on from the mother [6,26]. Although rare, severe and prolonged deficiency states can cause obstructed labour in the mother [27] and also congenital rickets in the newborn [28-30]. Apart from the mother, investigations in anyone presenting with osteomalacia should certainly extend to all members of the family, as it is extremely likely that they all share the same risk factors such as skin colour (dark skin produces less vitamin D than light skin), dietary habits (diet low in dairy products or lack of supplements), cultural habits (covered clothing, sun avoidance) and geographic location (reduced sunlight and reduced skin synthesis of vitamin D at high latitude) [6]. At highest risk of nutritional rickets and osteomalacia is the dark skinned population residing in high latitude countries with restricted sunlight, lack of robust vitamin D supplementation programs and mandatory food fortification

policies [5,9,31-34]. In low and middle income countries with abundant sunshine, the populations at highest risk are those with dietary calcium deficiency and cultural whole body clothing [2-4].

How is nutritional osteomalacia diagnosed?

Osteomalacia is diagnosed on bone histomorphometry and is defined by a combination of osteoid thickness $> 12.5 \mu\text{m}$ and a mineralization lag time of >100 days [11]. Hypovitaminosis D osteopathy or pre-osteomalacia is characterized by an increase mainly in osteoid surface with a slight increase in osteoid thickness (usually just $<12.5 \mu\text{m}$) [11]. The availability of normative data has enabled the use of iliac bone histomorphometry also in growing children [35]. There is no significant natural variation with age (1.5 to 22.9 years) in osteoid thickness [n=58, median $6.1 \mu\text{m}$ (range 3.9–10.0), $P=0.38$] and mineralization lag time [n=48, median 15.1 days (range 8.7–29.1), $P=0.75$] [35].

The need for invasive bone biopsy and histomorphometry for a conclusive diagnosis has been perceived as discouraging and hence biopsies are rarely performed. However, it is not impossible to make a diagnosis without a bone biopsy and non-invasive diagnostic criteria have been proposed (**Box 1**) [36,37], but are not universally adopted or suitable for all age groups.

Box 1: Diagnostic criteria for adult osteomalacia proposed by a Japanese group [36]

- (a) Hypophosphataemia or hypocalcaemia
 - (b) High bone alkaline phosphatase level
 - (c) Clinical symptoms: muscle weakness or bone pain
 - (d) Low Bone Mineral Density: less than 80 % of young adult mean
 - (e) Abnormal imaging findings: multiple uptake by bone scintigraphy or Looser's zone by X-ray
- Definite osteomalacia: patients who have (a)–(e)
- Possible osteomalacia: patients who have (a), (b), and 2 of (c)–(e)

Whilst these proposed criteria may help diagnose adult patients with severe and/or prolonged osteomalacia, those with mild to moderate disease and non-specific symptoms will be missed as features such as hypophosphataemia and low BMD or radiological changes only occur late in the disease process (**Figure 2**).

We concur with others that it should be possible to diagnose nutritional osteomalacia non-invasively based on a combination of risk factors including a simple dietary history [21], clinical features, laboratory markers and some radiological features [23,36,37]. In patients with nutritional osteomalacia, the predisposing risk factors are obvious (geographic location, dark skin colour, whole body clothing) and a history of low calcium diet is imperative. In most cases, serum calcium and phosphate are initially normal in the early stages of the disease due to compensation by raised parathyroid hormone (PTH). A decreasing serum calcium level below its set-point is detected by the calcium sensing receptor in the parathyroid gland's chief cells which stimulates PTH release. The raised PTH maintains calcium supply in the body by releasing calcium stored in the bones through osteoclastic bone resorption, increasing renal calcium absorption and stimulating 1-hydroxylase activity to maximize calcitriol synthesis [38]. Unless intervened at this stage with vitamin D

and/or calcium supplementation, long standing secondary hyperparathyroidism will eventually lead to failure of compensatory mechanisms causing renal phosphate wasting, ultimately manifesting as hypophosphataemia and/or hypocalcaemia. Hence, a raised PTH is a very good indicator of osteomalacia in risk groups with low 25OHD concentrations and/or low dietary calcium. 25OHD concentrations below 25 nmol/L are linked with osteomalacia on histomorphometry and almost always associated with raised serum alkaline phosphatase (ALP) and PTH concentrations [15]. Therefore, a raised ALP [37,38] in children or more specifically, bone specific alkaline phosphatase (BALP) in adults [36] are useful diagnostic serum markers in this setting. Here, we propose clinical criteria for the non-invasive diagnosis of osteomalacia that apply to all age groups, taking into account age- and sex-specific laboratory reference data (**Box 2**).

Box 2: Proposed diagnostic criteria for osteomalacia in children and adults

- 1) High PTH
- 2) High ALP
- 3) Low dietary calcium (<300 mg/day) and/or low serum 25OHD (<30 nmol/L)
- 4) Low urinary calcium

Presence of the above features in the absence of renal/liver disease suggests a diagnosis of osteomalacia.

Presence of clinical symptoms and radiological features (Looser's zone fractures) help confirm the diagnosis in late stages (**Figure 2**).

Looser's zone fractures on radiographs, low BMD on DXA, increased tracer uptake on bone scintigraphy are not specific to osteomalacia. However, these radiological changes occur in the late stages of the disease where laboratory evidence of osteomalacia/rickets should already be overwhelming, thereby limiting their clinical utility. Other markers of bone resorption (i.e. carboxy-terminal telopeptide of type I

collagen, amino-terminal telopeptide of type I collagen and deoxypyridinoline) or formation (i.e. amino-terminal propeptide of type I procollagen and osteocalcin) are of uncertain value in distinguishing between osteomalacia and osteoporosis [39].

What are the practical difficulties in diagnosing osteomalacia in the community?

Non-specific clinical presentation and lack of diagnostic markers:

A high index of suspicion is necessary to diagnose osteomalacia in adults. Patients often present to general practitioners, rheumatologists or neurologists and nonspecific clinical features may lead to a delay in diagnosis and unnecessary investigations [11,21,23]. Specific knowledge of the main risk factors for osteomalacia such as ethnicity and dairy intake may be lacking. Physicians also tend to measure 25OHD only rather than the diagnostically far more important ALP and PTH. Unlike rickets which is a radiological diagnosis, osteomalacia is a histological diagnosis. Even in patients with osteomalacia, environmental causes are rarely assumed leading to a number of unnecessary investigations in the search for pathological causes.

Differential diagnoses:

1. Primary hyperparathyroidism: For the less experienced, increased PTH concentrations may also raise suspicion of primary hyperparathyroidism. However, in contrast to the low or normal serum calcium seen in secondary hyperparathyroidism, patients with primary hyperparathyroidism have high serum and urinary calcium. The fact that serum calcium is usually normal in

osteomalacia, and thus a very poor marker of the body's calcium status, is not well known in the community.

2. Osteoporosis: Long standing osteomalacia may be difficult to distinguish from osteoporosis as both conditions present with fractures and markedly reduced BMD on DXA scans [11]. Moreover, nutritional osteomalacia may co-exist with osteoporosis in old age, hence prevention and treatment of vitamin D or calcium deficiency in this age group is recommended [24].
3. Malignancy: In the absence of prompt diagnosis and treatment, prolonged deficiency can mimic malignancy; clinically (weight loss) and radiologically (osteopenia on radiographs and widespread increased uptake on bone scintigraphy) [11,21]. Very rarely, FGF23 production by cancer cells may lead to tumour-induced osteomalacia (TIO), independent of vitamin D status or calcium intake.

Why is it important to diagnose nutritional osteomalacia?

Whilst several reports highlight the resurgence of nutritional rickets in developed countries [40-45], osteomalacia which goes hand in hand with rickets and likely affects a large proportion of the adult at-risk population is somewhat neglected.

Disease burden: The national diet and nutritional survey in the United Kingdom reports low 25OHD concentrations (<25 nmol/L) in nearly 39% of the population in the 19-65 years age group [44] despite a profound underrepresentation of the dark skinned ethnic groups who are most at risk. However, the lack of additional metabolic bone markers (ALP, PTH) precludes the assessment of osteomalacia.

Risk groups: The BAME group is at greatest risk of osteomalacia.

We have previously highlighted that two thirds of investigated family members of BAME infants with nutritional rickets showed biochemical signs of osteomalacia (raised ALP and PTH, and 25OHD < 30 nmol/L) [6].

Immigrant /dark skinned mothers have lower 25OHD concentrations compared to white mothers [32,33,46]. Inspecting data from studies measuring PTH and/or ALP in addition to 25OHD concentrations shed further light on the prevalence of osteomalacia in the BAME population. A study of pregnant women in the north of England reported significantly higher PTH and lower 25OHD concentrations, in South Asian women compared to European women [32]. Although the study was not focussed on identifying osteomalacia, the extent of biochemical osteomalacia revealed by raised PTH was alarming. South Asian women when compared to European women had much lower median 25OHD (interquartile range in nmol/L) [n=783, 14.7 (9.7, 23.4) and n=596, 37.9 (26.7, 58.6) respectively, P .001] and higher median PTH (interquartile range in pmol/L) [n=780, 7.6 (5.0, 11.0) and n=594, 3.2 (2.3, 4.5) respectively, P<0.001] [32]. These findings were resonated in another study from the south of England reporting significant differences in PTH between the South Asian and Caucasian population (4.3 and 2.6 pmol/L respectively in autumn, P<0.001) [46].

Morbidity and mortality: Osteomalacia is likely to contribute not just to morbidity but also mortality [6] in the BAME population. Effects of nutritional osteomalacia due to vitamin D deficiency can be debilitating causing not only fatigue and malaise but also severe proximal myopathy [22] and muscle weakness [47,48]. Nutritional osteomalacia is entirely preventable [3] and easily reversible if identified early [11,49]. Undiagnosed osteomalacia however adversely affects quality of life,

moreover prolonged secondary hyperparathyroidism causes irreversible bone damage with cortical thinning [49] and increased lifetime fracture risk [50].

What are the future research recommendations?

Exploring the hidden body of the iceberg of nutritional osteomalacia [51] will have a significant benefit for designing public health policies such as vitamin D / calcium supplementation [31] and food fortification [52]. A good way of assessing the extent of the problem would be to incorporate bone metabolic markers such as ALP and PTH into national diet and nutritional surveys. The national surveys in high-income countries should include more people of BAME origin in order to be equally representative and avoid under-reporting the scale of the problem. Similar surveys in low and middle income settings are also important to study the effect of concomitant micronutrient deficiencies (such as iron and zinc) on vitamin D and/or calcium deficiency. Dynamic bone histomorphometry studies are needed to explore the relationship of clinical (dietary calcium intake) and laboratory markers (PTH, ALP, 25OHD) with bone tissue mineralization in specific population groups (based on age, gender, ethnicity, pregnancy).

Conclusions: Nutritional osteomalacia is widespread but the true prevalence remains unidentified. We propose non-invasive diagnostic criteria and call for studies exploring the true prevalence of hidden osteomalacia, in order to design better preventative public health policies.

Conflict of interest: None declared

Funding: None received

REFERENCES

- [1] S. Uday, W. Högler, Rickets and Osteomalacia, In: I Huhtaniemi and L Martini (Eds.), *Encyclopedia of Endocrine Diseases*, 2nd edition, vol. 5, pp. 334-349. Oxford: Academic Press. Elsevier Inc., 2019. doi:10.1016/B978-0-12-801238-3.65426-0.
- [2] S. Uday, W. Högler, Nutritional Rickets and Osteomalacia in the Twenty-first Century: Revised Concepts, Public Health, and Prevention Strategies, *Curr. Osteoporos. Rep.* 15 (2017) 293–302. doi:10.1007/s11914-017-0383-y.
- [3] C.F. Munns, N. Shaw, M. Kiely, B.L. Specker, T.D. Thacher, K. Ozono, T. Michigami, D. Tiosano, M.Z. Mughal, O. Mäkitie, L. Ramos-Abad, L. Ward, L.A. Dimeglio, N. Atapattu, H. Cassinelli, C. Braegger, J.M. Pettifor, A. Seth, H.W. Idris, V. Bhatia, J. Fu, G. Goldberg, L. Sävendahl, R. Khadgawat, P. Pludowski, J. Maddock, E. Hyppönen, A. Oduwole, E. Frew, M. Aguiar, T. Tulchinsky, G. Butler, W. Högler, Global Consensus Recommendations on Prevention and Management of Nutritional Rickets., *J. Clin. Endocrinol. Metab.* 101 (2016) 394–415.
- [4] A.L. Creo, T.D. Thacher, J.M. Pettifor, M.A. Strand, P.R. Fischer, Nutritional rickets around the world: an update, *Paediatr. Int. Child Health.* 37 (2017) 84–98. doi:10.1080/20469047.2016.1248170.
- [5] S. Uday, W. Högler, Prevention of rickets and osteomalacia in the UK: political action overdue, *Arch. Dis. Child.* 103 (2018) 901–906. doi:10.1136/archdischild-2018-314826.
- [6] S. Uday, N. Fratzi-Zelman, P. Roschger, K. Klaushofer, A. Chikermane, V. Saraff, T. Tulchinsky, T.D. Thacher, T. Marton, W. Högler, Cardiac, bone and growth plate manifestations in hypocalcemic infants: revealing the hidden body of the vitamin D deficiency iceberg, *BMC Pediatr.* 18 (2018) 1–9. doi:10.1186/s12887-018-1159-y.
- [7] T.D. Thacher, P. Pludowski, N.J. Shaw, M.Z. Mughal, C.F. Munns, W. Högler, Nutritional rickets in immigrant and refugee children, *Public Health Rev.* 37 (2016) 1–10. doi:10.1186/s40985-016-0018-3.
- [8] M. Goldacre, N. Hall, D.G.R. Yeates, Hospitalisation for children with rickets in England: A historical perspective, *Lancet.* 383 (2014) 597–598. doi:10.1016/S0140-6736(14)60211-7.
- [9] M. Priemel, C. Von Dörmann, T.O. Klatte, S. Kessler, J. Schlie, S. Meier, N. Proksch, F. Pastor, C. Netter, T. Streichert, Bone Mineralization Defects and Vitamin D Deficiency : Histomorphometric Analysis of iliac crest bone biopsies and circulating 25-hydroxyvitamin D in 675 patients. *J. Bone Miner. Res.* 25 (2010) 305–312. doi:10.1359/jbmr.090728.
- [10] A.M. Parfitt, *Osteomalacia and Related Disorders*, 3rd ed., Academic Press, New York, 1998. doi:10.1016/B978-012068700-8/50012-8.
- [11] A. Bhan, S. Qiu, S.D. Rao. Bone histomorphometry in the evaluation of osteomalacia, *Bone Reports.* 8 (2018) 125–134. doi:10.1016/j.bonr.2018.03.005.

- [12] A.M. Parfitt, S. Qiu, D.S. Rao. The mineralization index — A new approach to the histomorphometric appraisal of osteomalacia, 35 (2004) 320–325. doi:10.1016/j.bone.2004.02.016.
- [13] W. Högler, L. Ward, Osteoporosis in children with chronic disease, in: *Calcium Bone Disord. Child. Adolesc. Second Ed.*, 2015: pp. 176–195. doi:10.1159/000381045.
- [14] J.M. Kling, B.L. Clarke, N.P. Sandhu, Osteoporosis prevention, screening, and treatment: a review. *J. Womens. Health (Larchmt)*. 23 (2014) 563–72. doi:10.1089/jwh.2013.4611.
- [15] A. Bhan, A.D. Rao, S.D. Rao, Osteomalacia as a Result of Vitamin D Deficiency, *Endocrinol. Metab. Clin. North Am.* 39 (2010) 321–331.
- [16] S. Ladhani, L. Srinivasan, C. Buchanan, J. Allgrove, Presentation of vitamin D deficiency. *Arch. Dis. Child.* 89 (2004) 781–784. doi:10.1136/adc.2003.031385.
- [17] P.D. Robinson, W. Högler, M.E. Craig, C.F. Verge, J.L. Walker, a C. Piper, H.J. Woodhead, C.T. Cowell, G.R. Ambler, The re-emerging burden of rickets: a decade of experience from Sydney. *Arch. Dis. Child.* 91 (2006) 564–568. doi:10.1136/adc.2004.069575.
- [18] E. Basatemur, A. Sutcliffe, Incidence of hypocalcemic seizures due to vitamin D deficiency in children in the United Kingdom and Ireland. *J. Clin. Endocrinol. Metab.* 100 (2015) E91–E95. doi:10.1210/jc.2014-2773.
- [19] S. Maiya, I. Sullivan, J. Allgrove, R. Yates, M. Malone, C. Brain, N. Archer, Q. Mok, P. Daubeney, R. Tulloh, M. Burch. Hypocalcaemia and vitamin D deficiency: an important, but preventable, cause of life-threatening infant heart failure., *Heart.* 94 (2008) 581–584. doi:10.1136/hrt.2007.119792.
- [20] I. Scheimberg, L. Perry, Does Low Vitamin D Have a Role in Pediatric Morbidity and Mortality ? An Observational Study of Vitamin D in a Cohort of 52 Postmortem Examinations, *Pediatr. Dev. Pathol.* 17 (2014) 455–464. doi:10.2350/14-05-1491-OA.1.
- [21] C.K. Noh, M.J. Lee, B.K. Kim, Y.-S. Chung, A Case of Nutritional Osteomalacia in Young Adult Male, *J. Bone Metab.* 20 (2013) 51. doi:10.11005/jbm.2013.20.1.51.
- [22] Y.A. Al-Said, H.S. Al-Rached, H.A. Al-Qahtani, M.M.S. Jan, Severe Proximal Myopathy with Remarkable Recovery after Vitamin D Treatment, *Can. J. Neurol. Sci. / J. Can. Des Sci. Neurol.* 36 (2009) 336–339. doi:10.1017/S0317167100007083.
- [23] S.W. Kim, N. Hong, Y. Rhee, Y.C. Choi, H.Y. Shin, S.M. Kim, Clinical and laboratory features of patients with osteomalacia initially presenting with neurological manifestations, *Osteoporos. Int.* 29 (2018) 1617–1626. doi:10.1007/s00198-018-4501-1.
- [24] T.J. Aspray, C. Bowring, W. Fraser, N. Gittoes, M.K. Javaid, H. Macdonald, S.

- Patel, P. Selby, N. Tanna, R.M. Francis, National osteoporosis society vitamin D Guideline Summary, *Age Ageing*. 43 (2014) 592–595. doi:10.1093/ageing/afu093.
- [25] M.C. Cohen, A. Offiah, A. Sprigg, M. Al-Adnani, Vitamin D deficiency and sudden unexpected death in infancy and childhood: a cohort study, *Pediatr. Dev. Pathol.* 16 (2013) 292–300. doi:10.2350/13-01-1293-OA.1.
- [26] W. Högler, Complications of vitamin D deficiency from the foetus to the infant: One cause, one prevention, but who's responsibility?, *Best Pract. Res. Clin. Endocrinol. Metab.* 29 (2015) 385–398. doi:10.1016/j.beem.2015.03.003.
- [27] J.C. Konje, O.A. Ladipo, Nutrition and obstructed labor, *Am. J. Clin. Nutr.* 72 (2000) 291s–297s.
- [28] Ö. Erdeve, B. Atasay, S. Arsan, Z. Şıklar, G. Öcal, M. Berberoğlu, Hypocalcemic seizure due to congenital rickets in the first day of life, *Turk. J. Pediatr.* 49 (2007) 301–303.
- [29] C.R. Paterson, D. Ayoub, Congenital rickets due to vitamin D deficiency in the mothers, *Clin. Nutr.* 34 (2015) 793–798. doi:10.1016/j.clnu.2014.12.006.
- [30] A.T.H. Elidrissy, The Return of Congenital Rickets, Are We Missing Occult Cases?, *Calcif. Tissue Int.* 99 (2016) 227–236. doi:10.1007/s00223-016-0146-2.
- [31] S. Uday, A. Kongjonaj, M. Aguiar, T. Tulchinsky, W. Högler, Variations in infant and childhood Vitamin D supplementation programs across Europe and factors influencing adherence, *Endocr. Connect.* 6 (2017) 667–675. doi:10.1530/EC-17-0193.
- [32] D.C. Whitelaw, A.J. Scally, D.J. Tuffnell, T.J. Davies, W.D. Fraser, R.S. Bhopal, J. Wright, D.A. Lawlor, Associations of circulating calcium and 25-hydroxyvitamin D with glucose metabolism in pregnancy: A cross-sectional study in European and south Asian women, *J. Clin. Endocrinol. Metab.* 99 (2014) 938–946. doi:10.1210/jc.2013-2896.
- [33] F. Cadario, S. Savastio, C. Magnani, T. Cena, V. Pagliardini, G. Bellomo, M. Bagnati, M. Vidali, E. Pozzi, S. Pamparana, M. Zaffaroni, G. Genoni, G. Bona, High prevalence of vitamin D deficiency in native versus migrant mothers and newborns in the North of Italy: A call to act with a stronger prevention program, *PLoS One*. 10 (2015). doi:10.1371/journal.pone.0129586.
- [34] I. Bergstrom, M. Palmer, J. Persson, A. Blanck, Observational study of vitamin D levels and pain in pregnant immigrant women living in Sweden., *Gynecol. Endocrinol.* 30 (2014) 74–77. doi:10.3109/09513590.2013.856408.
- [35] F.H. Glorieux, R. Travers, A. Taylor, J.R. Bowen, F. Rauch, M. Norman, A.M. Parfitt, Normative Data for Iliac Bone Histomorphometry in Growing Children, *Bone*. 26 (2000) 103–109.
- [36] S. Fukumoto, K. Ozono, T. Michigami, M. Minagawa, Pathogenesis and diagnostic criteria for rickets and osteomalacia — proposal by an expert panel

- supported by the Ministry of Health , Labour and Welfare , Japan , the Japanese Society for Bone and Mineral Research , and the Japan Endocrine Society, *J. Bone Miner. Metab.* 33 (2015) 467–473. doi:10.1007/s00774-015-0698-7.
- [37] C.T. Bingham, L.A. Fitzpatrick, Noninvasive testing in the diagnosis of osteomalacia, *Am. J. Med.* 95 (1993) 519–523. doi:10.1016/0002-9343(93)90335-M.
- [38] N. Atapattu, N. Shaw, W. Högler, Relationship between serum 25-hydroxyvitamin D and parathyroid hormone in the search for a biochemical definition of vitamin D deficiency in children, *Pediatr. Res.* 74 (2013) 552–556. doi:10.1038/pr.2013.139.
- [39] M.C. Vlot, M. Den Heijer, R.T. De Jongh, M.G. Vervloet, W.F. Lems, R. De Jonge, A.C. Heijboer, Clinical utility of bone markers in various diseases, *Bone.* 114 (2018) 215–225. doi:10.1016/j.bone.2018.06.011.
- [40] S.F. Ahmed, C. Franey, H. McDevitt, L. Somerville, S. Butler, P. Galloway, L. Reynolds, M.G. Shaikh, M. Wallace, Recent trends and clinical features of childhood vitamin D deficiency presenting to a children’s hospital in Glasgow., *Arch. Dis. Child.* 96 (2011) 694–696. doi:10.1136/adc.2009.173195.
- [41] J.H. Davies, N.J. Shaw, Preventable but no strategy: vitamin D deficiency in the UK., *Arch. Dis. Child.* 96 (2011) 614–615. doi:10.1136/adc.2010.191627.
- [42] A. Prentice, Vitamin D deficiency: A global perspective, *Nutr. Rev.* 66 (2008) S153-64. doi:10.1111/j.1753-4887.2008.00100.x.
- [43] H.E. Meyer, K. Skram, I.A. Berge, A.A. Madar, H.J. Bjørndalen, Nutritional rickets in Norway: A nationwide register-based cohort study, *BMJ Open.* 7 (2017) 1–6. doi:10.1136/bmjopen-2016-015289.
- [44] B. Bates, A. Lennox, A. Prentice, C. Bates, P. Page, S. Nicholson, G. Swan, National Diet and Nutrition Survey : Results from Years 1-4 (combined) of the Rolling Programme. Executive Summary, 2014. doi:10.1017/CBO9781107415324.004.
- [45] B.J. Wheeler, N.P. Dickson, L.A. Houghton, L.M. Ward, B.J. Taylor, Incidence and characteristics of Vitamin D deficiency rickets in New Zealand children: A New Zealand Paediatric Surveillance Unit study, *Aust. N. Z. J. Public Health.* 39 (2015) 380–383. doi:10.1111/1753-6405.12390.
- [46] A.L. Darling, K.H. Hart, H.M. MacDonald, K. Horton, A.R. Kang’Ombe, J.L. Berry, S.A. Lanham-New, Vitamin D deficiency in UK South Asian Women of childbearing age: A comparative longitudinal investigation with UK Caucasian women, *Osteoporos. Int.* 24 (2013) 477–488. doi:10.1007/s00198-012-1973-2.
- [47] L. Granlund, M. Norberg, A. Ramnemark, C. Andersson, M. Lindkvist, E. Fhärm, Vitamin D is associated with lower limb muscle strength and grip strength in Middle Eastern– and African-born immigrants in Sweden, *Nutr. Res.* 59 (2018) 29–35. doi:10.1016/j.nutres.2018.07.009.

- [48] M. Englund, J. Persson, I. Bergström, Lower pain and higher muscular strength in immigrant women with vitamin D deficiency following vitamin D treatment, *Int. J. Circumpolar Health*. 76 (2017) 1340547. doi:10.1080/22423982.2017.1340547.
- [49] R. Bhambri, V. Naik, N. Malhotra, S. Taneja, S. Rastogi, U. Ravishanker, A. Mithal, Changes in bone mineral density following treatment of osteomalacia. *J. Clin. Densitom.* 9 (2006) 120–127.
- [50] A.M. Parfitt, D.S. Rao, J. Stanciu, A.R. Villanueva, M. Kleerekoper, B. Frame, Irreversible bone loss in osteomalacia. Comparison of radial photon absorptiometry with iliac bone histomorphometry during treatment, *J. Clin. Invest.* 76 (1985) 2403–2412. doi:10.1172/JCI112253.
- [51] A. Spiro, J.L. Buttriss, Vitamin D: An overview of vitamin D status and intake in Europe, *Nutr. Bull.* 39 (2014) 322–350. doi:10.1111/nbu.12108.
- [52] L.J. Black, K.M. Seamans, K.D. Cashman, M. Kiely, An updated systematic review and meta-analysis of the efficacy of vitamin D food fortification. *J. Nutr.* 142 (2012) 1102–8. doi:10.3945/jn.112.158014.

Figure 1: Spectrum of clinical presentation of nutritional rickets and osteomalacia from conception to old age. Clinically evident symptoms of rickets as well as osteomalacia only represent the tip of the iceberg. The iceberg's hidden part (widespread solar vitamin D and dietary calcium deficiency) in the majority remains undiagnosed.

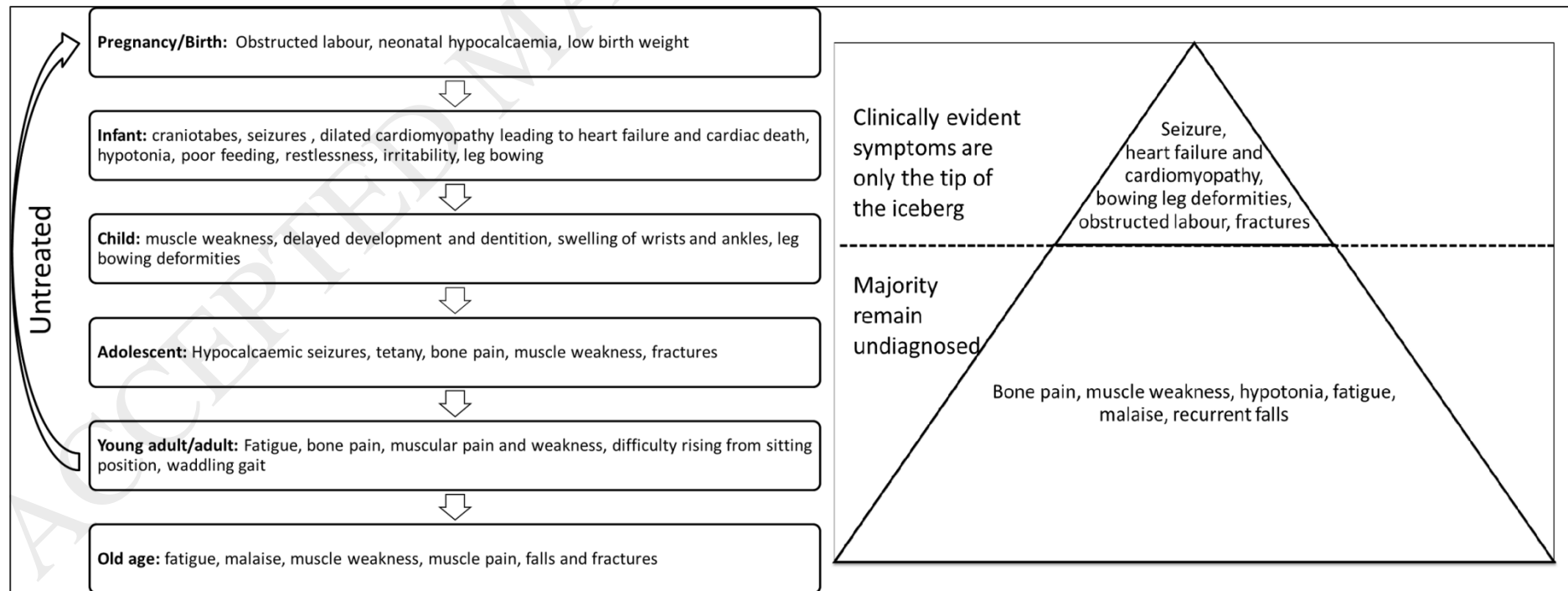


Figure 2: Stages of calcium deprivation, secondary to vitamin D and/or dietary calcium deficiency, that lead to osteomalacia in at risk individuals of all age groups. [Modified from Uday S, Högl W. Nutritional Rickets and Osteomalacia in the Twenty-first Century: Revised Concepts, Public Health, and Prevention Strategies. *Curr Osteoporos Rep.* 2017;15(4):293–302 in accordance with Creative Commons license (<http://creativecommons.org/licenses/by/4.0/>)].

